

*Full Length Research Paper*

# **Histopathology of Nile Tilapia (*Oreochromis niloticus*) juveniles exposed to aqueous and ethanolic extracts of *Ipomoea aquatica* leaf**

**Ayoola Simeon Oluwatoyin**

Department of Marine Sciences, University of Lagos, Akoka, Yaba, Lagos State, Nigeria.  
E-mail: [soayoola@yahoo.com](mailto:soayoola@yahoo.com), [sayoola@unilag.edu.ng](mailto:sayoola@unilag.edu.ng). Tel: +234(80)34650102.

Accepted 17 June, 2011

The effect of aqueous and ethanolic extracts of *Ipomoea aquatica* leaf on the histopathology of selected organs of the fresh water *Oreochromis niloticus* was investigated. The differential acute toxicity of aqueous and ethanolic extracts of *I. aquatica* leaf on Nile Tilapia, *O. niloticus* were carried out under laboratory conditions. The LC<sub>50</sub> after 96 h of exposure for aqueous and ethanolic extracts of *Ipomoea aquatica* were 2.659 and 0.196 g/L, respectively. These values showed that ethanolic extract of *I. aquatica* was more toxic than its aqueous extract. Signs of agitated behaviours, respiratory distress and abnormal nervous behaviours including eventual deaths were observed in exposed fish. Control fish neither died nor exhibited any unusual behaviour. Histopathological changes of gill, liver and muscle were noticed when *O. niloticus* was exposed to aqueous extract of *I. aquatica* for 96 h. In the gills, filament cell showed lesion, necrosis, malignancy, cellular degeneration and inflammation. In the liver, there was vacuolation of hepatocytes, inflammation and necrosis. In the muscle there was mild lesion, necrosis, inclusion bodies, inflammation and cellular degenerations. Similar result was obtained when the tested organism (*O. niloticus*) was exposed to ethanolic extract of *I. aquatica* for the same duration and under the same laboratory conditions. But the level of tissue and organ degeneration is more severe in the case of the ethanolic extract than in aqueous extract. This investigation revealed that leaf of *I. aquatica* has piscicidal property and can be put into use in the control and management of fish ponds by farmers. Therefore, this plant can actually be use as a biological control in eradicating predators and unwanted organisms in the ponds by farmer instead of using agrochemicals.

**Key words:** Histopathology, *Ipomoea aquatica*, *Oreochromis niloticus*.

## **INTRODUCTION**

Piscicides are botanicals whose extract are toxic or poisonous to fish (Murthy et al., 1986). They are often used to control competing species in fish production especially in small water bodies/enclosures, eradicate predators to control parasites, and conserve or restore native species but their uses are encouraged because of their less toxicity to aquatic organisms and non degradation to the environment (Olufayo, 2009).

There are many indigenous sources of botanical fish toxicants in Nigeria that are extremely toxic to a wide range of animals including fish; some of these plants include: *Derris elliptica*, *Tephrosia vogelii*, *Acacia pennata*, *Tetraplera tetraptera*, *Mundulea sericea*, *Boerhavia coccinea* (Olufayo, 2009). The introduction of

these plant extracts in the aquatic ecosystems could eventually lead to physiological stress in aquatic organisms and ultimately reduction in aquatic productivity (Olufayo, 2009). Many plants contain chemicals which have traditionally been used to harvest fish in almost all parts of the world. Fish farmers in Nigeria have persistently and indiscriminately abused these natural plant piscicides by using much higher concentrations than necessary, causing mass mortality of fish in ponds, contaminating the freshwater bodies and affecting non target organisms (Jennes, 1967).

The physical and chemical changes in aqueous environment often cause some physiological changes in fish, thus, the water quality of an aquatic body is very

crucial because it determines the productivity and other parameters necessary for fish survival. Many countries including Nigeria have legislated against the use of chemical poisons in aquatic systems and instead have policies favouring the use of natural bio-degradable alternatives to remove unwanted fish species in aquatic systems (Wang and Huffman, 1991; Olufayo, 2009).

Unwanted fishes may enter aquaculture farms through water supplies or along with seed brought into the fish farm. Occasional draining of the pond and fishing are usually inadequate to control and eradicate unwanted fishes. The best way of ensuring total eradication of unwanted fishes is through the use of fish toxicants in the pond water (Chakroff, 1976).

The use of piscicides as a tool in pond management during pond preparation to get rid of predators before fish stocking is an important tool. Ideally, ponds should be sundried and the pond bottom cracked dried to help get rid of fish predators. However, this practice is not always possible, particularly during the wet season.

Moreover, farmers who are always in a hurry to prepare their ponds always resort to the use of inorganic fish toxicants (Cagauan, 1995). In view of this, farmers resort to nonconventional and unregistered fish toxicants such as agro-pesticides and sodium cyanide because they are fast acting and readily available in the market. However, these chemicals may have negative effects on the environment and farmers' health (Ayoola, 2008).

Hence, there is a need to explore other environment and health-friendly fish toxicants such as botanical plants with piscicidal activity. Plants are virtually inexhaustible source of structurally diverse biologically active substances (Istvan, 2000). Some plants contain compounds of various classes that have insecticidal, piscicidal and molluscicidal properties. Unlike synthetic chemical pesticides which leave harmful residues in the aquatic environment (Koesomadinata, 1980), botanical insecticides are believed to be more environments friendly because they are easily biodegraded and leave no residues in the environment. Since some of these pesticidal compounds present in plants were also toxic to fishes, botanical pesticides can be used as piscicide to eradicate unwanted fishes in the pond. Many plants from different families have been applied for catching fish all over the world. Examples of these plants are of the genera *Derris*, *Tephrosia* and *Lonchocarpus* of the family Leguminosae. The toxic parts of plants employed as fish poisons include roots, seeds, fruits, bark, latex or leaves.

Agrochemical, such as pesticides especially chlorinated hydrocarbons are employed as part of the integrated farming practice to protect crops and animals from insects, weeds and diseases. Widespread use of pesticide on farm is now a worldwide phenomenon (Omitoyin et al., 2006). The aquatic ecosystem as a greater part of the natural environment is also faced with the threat of a shrinking genetic base and biodiversity due to indiscriminate use of pesticides (Omitoyin et al., 2006). The introduction of most chemicals into the

aquatic environment occurs both directly and indirectly and the accumulative lethal effect of the toxicants on aquatic organisms is extremely hazardous to fish (Tumanda, 1980).

Pesticides become readily available in the food chain and subsequent bioaccumulate in both aquatic and terrestrial flora and fauna, with possible unquantifiable disastrous consequences on the ecosystem (Odiete, 1999). Due to the residual effects of pesticides, important organ like kidney, liver, gills, stomach, brain, muscle and genital organs are damaged in fish exposed to pesticide.

*Ipomoea aquatica* is a member of the morning glory family, Convolvulaceae, which contains 500 species. *I. aquatica* and *I. fistula* are the only aquatic species in the genus, which also includes the sweet potato (*Ipomoea batatas* L.) (Cook, 1990). *I. aquatica* has been cultivated for its edible shoots and medicinal properties but sometimes, it is considered to be a serious weed.

The test organism is *Oreochromis niloticus* (juveniles). It is a member of the family cichlidae. It is considered as one of the organism suitable for toxicity test. They can grow both in fresh water and brackish water conditions. Some members of this genus are omnivorous feeders which can filter feed on plankton as well as accepting larger food particles. It is a native to West, Central and East Africa and it has been introduced to many other countries throughout the tropics and beyond (Arrignon, 1998). Their ability to withstand extreme water temperature and low levels of dissolved oxygen make them suitable for use as test organism in most bioassay tests. This study intends to assess the piscicidal activity of extracts from *Ipomoea aquatica* as eradicator during pond preparation. The objectives of these studies are to determine the acute toxicity of *I. aquatica* on juveniles of *O. niloticus* and to investigate the histopathological effect of the toxicants (*I. aquatica*) on juveniles of *O. niloticus*.

## MATERIALS AND METHODS

Four hundred juveniles of *O. niloticus* were bought from a fish farm in Badagry, Lagos State. The juveniles were transported in two aerated polythene bags to the laboratory in the early hours of the morning (8:00 am). The water to be used for stocking of the juveniles was dechlorinated by exposing it to sun for a period of 48 h. The Nile Tilapia juveniles were kept in a rectangular glass tank and allowed to acclimatize to laboratory conditions for a period of 14 days in an already dechlorinated tap water. The stock tank was fixed with cosmo 10,000 air pump with voltage 220-240v, to aerate the water. The juveniles were fed twice daily using copen commercial supplementary feed (42% protein content). The water was changed daily to prevent accumulation of toxic waste. Experimentation was carried out under ambient laboratory conditions. Feeding of the juveniles stop a day before the bioassay test.

The fresh leaves of *I. aquatica* were collected along the Oge creek, University of Lagos Akoka, Lagos State. The extraction of *I. aquatica* was done using Ohaus triple 700 to 800 series weighing balance. The fresh leaves of (1 kg) were collected and washed well to remove any adhering foreign particles and soil materials. The washed leaves were oven dried at 48 °C for 36 h to prevent enzyme

**Table 1.** Mean physico-chemical parameters of the test concentrations (*Ipomoea aquatica*) on *Oreochromis niloticus* using aqueous extracts.

Concentration g/L	Do (mg/l)	Physico – chemical parameters		
		Salinity (‰)	pH	Temp (°C)
0.0	5.9±0.1	0	7.0	26.0±0.6
0.5	5.8±0.1	0	7.0	27.0±0.1
1.5	5.8±0.3	0	7.0±0.1	27.0±0.1
2.5	5.4±0.1	0	6.9±0.2	27.1±0.2
3.5	5.0±0.1	0	6.7±0.3	27.0±0.1
4.5	5.0±0.1	0	6.4±0.1	27.3±0.2

action. After drying, it was coarsely powdered and later soaked in 1 L. of clean water for 72 h. The solution was filtered through a muslin cloth to separate aqueous extract from residue. The aqueous solution was then kept in a black plastic container at room temperature, until the time of use. 1kg of coarsely powdered, well dried fresh leaves of *I. aquatica* was put in a soxhlet extractor with 250 ml of 98% absolute ethanol as the extracting solvent. The set up was placed on a heating mantle and heated for 3 to 4 h.

The solvent extract was transferred to a rotary evaporator, Buchii, type 661 (with vacuum pump). The solvent was recovered with the concentration of the extract of the dried leaves reduced up to 25% volume. The extract was then transferred from the rotary evaporating flask to 100 ml beaker and further concentrated in a hot-air oven at 80°C. The extract was a dark-brown pasty substance. The extract was collected and stored at room temperature in a black plastic material that will not allow light penetration. Salinity was measured by using a hand refractometer. pH was measured by the use of Hanna instrument pH 211-micro processor pH meters. Dissolved oxygen (DO) was measured with DO meter (model EUTECH DO 600) while water temperature was determined by simple mercury in glass thermometer, calibrated in centigrade (°C).

#### Bioassay procedures

The preliminary tests were carried out at first to determine suitable range of concentration for the bioassay experiment. The concentration ranges chosen for the aqueous and ethanolic extract of *I. aquatica* after preliminary test were: 0.5, 1.5, 2.5, 3.5, 4.5, 0.11, 0.21, 0.43, 0.53, 1.07g/L, respectively. These concentrations were carefully measured out to make up 8 litres of solution in 5 bioassays containers in triplicate. Another bioassay container with 8 litres of water, free of the extract, served as control.

In each of the container, 10 juveniles (8.7 ± 0.3) cm were introduced. Care was taken to minimize the stress on the fish by using a hand net to collect and drop the fish carefully into the rectangular plastic tanks. The *Tilapia* juveniles exposed to different concentration of ethanolic extract of *I. aquatica* were monitored for mortality at 24, 48, 72 and 96 h.

#### Statistical analysis

The quantal response (mortality) was analysed by probit analysis (Finney, 1980). Graph of Probit values were used against log dose values and were plotted using the line of best fit for a straight curve. The indices of toxicity were derived from a computer statistical programme SPSS.

One Way Analysis of Variance (ANOVA) and comparison of means by Student Newman test were used to test for statistical differences.

#### Histopathology

Fishes that died after 96 h of the bioassay test were put aside for histopathological analysis. The gill, liver and muscle of the fish were removed from both control and experimental group. These organs were fixed in Bouin's fluid in order to avoid autolysis.

Embedded tissues were mounted on the wooden block. Sections were constrained in 1% Eosin for 2 min, after which sections were wash. The dehydrated sections were cleared in xylene. The cleared sections were mounted in Diethyl butylphthalate xylene (DPX) and allow to dry. The mounted sections were viewed under the microscope using different objectives and the result was taken.

#### RESULTS

The test organisms showed distress in behaviour on introduction into the bioassay tanks. There were changes in the frequency of movement of the fish subjected to different concentrations of *I. aquatica*. Behavioral changes such as uncoordinated movements, somersaulting, excess secretion of mucus, erratic swimming and increase in operculum ventilation, respiratory distress, strong spasm, paralysis, and prior to the death, paleness of fish were observed during the exposure of fish to *I. aquatica*. The colour of the skin of fish exposed to the toxicant changed from normal darkly pigmentation in the dorsal and the lateral part.

The mean values obtained for the physico-chemical parameter of the test media throughout the period of the experiment are presented in Tables 1 and 2 for aqueous and ethanolic extract, respectively.

#### Effect of aqueous and ethanol extract of *ipomoea aquatica* on *oreochromis niloticus*

The result of the acute toxicity test of aqueous and ethanolic extract of the leaf of *I. aquatica* against *O. niloticus* juveniles at 24, 48, 72 and 96 h of exposure period is shown in Tables 3 and 4, respectively. Figures 1

**Table 2.** Mean physico-chemical parameters of the test concentrations (*I. aquatica*) on *O. niloticus* using ethanol extracts.

Concentration (g/L)	Do (mg/L)	Physico-chemical parameters		
		Salinity(‰)	pH	Temp (°C)
0.0	5.9±0.1	0	7.0	26.0±0.6
0.11	5.8±0.1	0	7.0	27.0±0.1
0.21	5.8±0.2	0	7.0	26.9±0.2
0.43	5.1±0.1	0	6.8±0.2	26.8±0.2
0.53	5.0±0.1	0	6.7±0.3	27.0±0.1
1.07	5.0±0.1	0	6.4±0.1	27.3±0.2

**Table 3.** Acute toxicity effect of aqueous extract of the leaf of *I. aquatica* against *O. niloticus* juvenile at 24, 48, 72 and 96 h exposure.

Exposure time (h)	LC <sub>50</sub> (95% C.L g/l)	LC <sub>95</sub> (95% C.L g/l)	LC <sub>5</sub> (95% C.L g/l)	Slope ± S.E	T.F	D.F	Probit line equation
24	9.178	41.394	2.035	2.514±0.93	1.00	3	Y=2.579+2.514X
48	9.157	40.822	0.800	1.554±0.49	1.00	3	Y=3.506+1.554X
72	4.623	37.035	0.240	1.280±0.36	1.99	3	Y=4.149+1.280X
96	2.659	31.485	0.225	1.532±0.35	3.35	3	Y=4.349+1.532X

L.C = Lethal concentration; T.F = Toxicity factor; S.E = Standard Error; D.F = Degree of freedom; C.L = Confidential Limit.

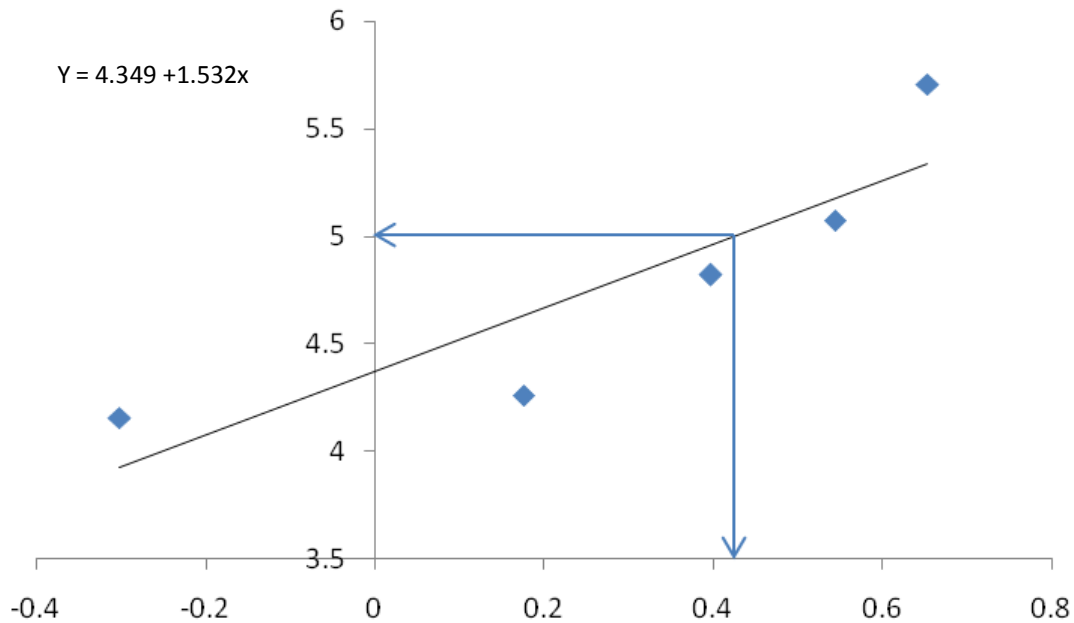
$$T.F = \frac{LC_{50} \text{ at 24 h}}{LC50 \text{ at any other period time}}$$

**Table 4.** Acute toxicity effect of ethanolic extract of the leaf of *I. aquatica* against *O. niloticus* juvenile at 24, 48, 72 and 96 h exposure.

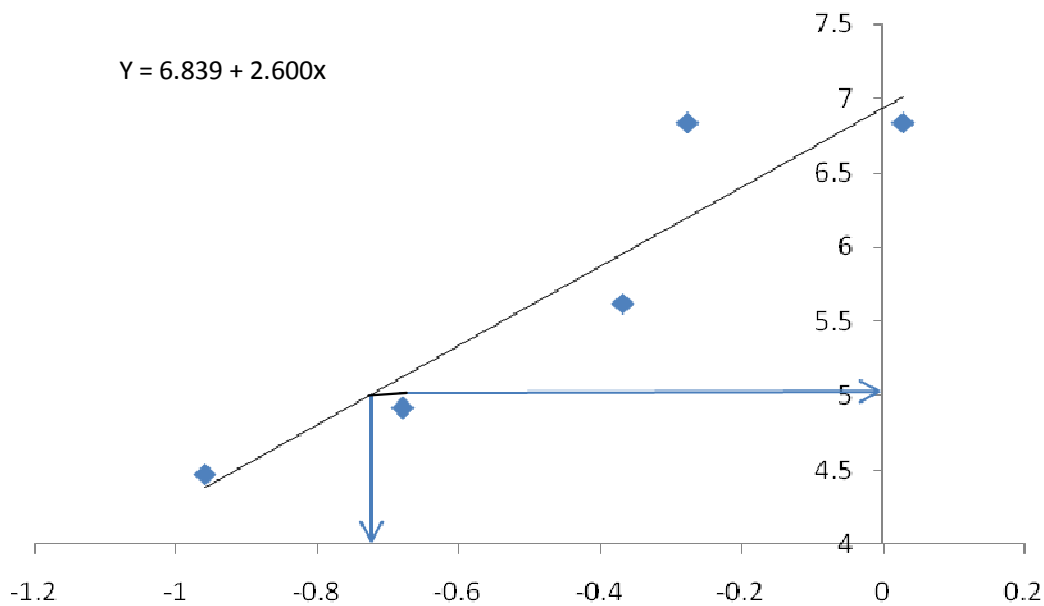
Exposure time (h)	LC <sub>50</sub> (95% C.L g/l)	LC <sub>95</sub> (95% C.L g/l)	LC <sub>5</sub> (95% C.L g/l)	Slope ± S.E	T.F	D.F	Probit line equation
24	0.642	1.692	0.244	3.910±0.64	1.00	3	Y=5.751+3.910X
48	0.391	1.468	0.104	2.863±0.41	1.64	3	Y=6.168+2.863X
72	0.276	1.189	0.064	2.594±0.39	2.33	3	Y=6.450+2.594X
96	0.196	0.842	0.046	2.600±0.41	3.28	3	Y=6.839+2.600X

L.C = Lethal concentration; T.F = Toxicity factor; S.E = Standard Error; D.F = Degree of freedom; C.L = Confidential Limit.

$$T.F = \frac{LC_{50} \text{ at 24 h}}{LC50 \text{ at any other period time}}$$



**Figure 1.** Linear relationship between probit response and log concentration of aqueous extract of *I. aquatica* on juveniles of *O. niloticus*.



**Figure 2.** Linear relationship between probit response and log concentration of ethanolic extract of *I. aquatica* on juveniles of *O. niloticus*.

and 2 shows the graph of probit response and log – dose drawn from the probit line equation tables. The LC<sub>50</sub> values obtained at 96 h for aqueous extract was 2.659 g/L while ethanolic extract was 0.196 g/L. Summaries of histopathological changes observed in the gill, liver and muscle of *O. niloticus* juveniles subjected to different concentrations of aqueous and ethanolic extract *I.*

*aquatica* for 96 h are presented in Tables 5 and 6. Histopathological effects of aqueous and ethanolic extracts on tissues (liver, gills, and muscles) of *O. niloticus* are presented in Plates 1a to f, 2a to f, 3a to f and 4a to e, 5a to e, 6a to e, respectively, where L= lesion; M= malignancy; N= necrosis; O= inflammation; P= pigment; Z= cellular degeneration; R= inclusion bodies.

**Table 5.** Histopathological changes of aqueous extract *I. aquatica* for 96 h.

Treatment concentration (g/L)	Hour of merit	Organs	Lesion	Malignancy	Necrosis	Inflammation	Pigment	Cellular degeneration	Inclusion bodies
0.0	96	Gill	-	-	-	-	-	-	-
		Liver	-	-	-	-	-	-	-
		Muscle	-	-	-	-	-	-	-
0.5	96	Gill	+	+	+	+	+	+	-
		Liver	+	-	+	+	-	-	-
		Muscle	-	++	+	+	-	+	++
1.5	96	Gill	+	+	-	+	+	-	-
		Liver	+	-	+	-	-	-	-
		Muscle	-	-	++	-	++	+	-
2.5	96	Gill	+	-	+	+	+	-	-
		Liver	-	-	+++	+	-	+	-
		Muscle	-	-	-	++	-	++	-
3.5	96	Gill	-	++	-	++	++	+	-
		Liver	++	-	+	++	-	+	-
		Muscle	++	++	-	++	++	-	-
4.5	96	Gill	-	+++	-	+++	+++	-	-
		Liver	+++	-	++	+	+	-	-
		Muscle	++	-	++	++	-	++	-

L=Lesion; M= Malignancy; N= Necrosis; O = Inflammation; P=Pigment; Z= cellular degeneration; R= inclusion bodies, - = completely absence, + = present, ++ = mild, +++ = severe. Treatment with negative signs indicated no histopathological changes were observed.

**Table 6.** Histopathological changes of ethanol extract of *I. aquatica* for 96 h.

Treatment concentration (g/L)	Hour of merit	Organs	Lesion	Malignancy	Necrosis	Inflammation	Pigment	Cellular degeneration	Inclusion bodies
0.0	96	Gill	-	-	-	-	-	-	-
		Liver	-	-	-	-	-	-	-
		Muscle	-	-	-	-	-	-	-
0.11	96	Gill	+	-	-	-	-	+	-
		Liver	+	-	+	-	-	-	-
		Muscle	+	+	+	-	-	-	-

Table 6. Contd.

0.21	96	Gill	+	-	-	-	-	+	-
		Liver	+	-	+	-	-	-	-
		Muscle	-	-	+	-	-	-	-
0.43	96	Gill	+	-	-	+	-	-	-
		Liver	+	+	-	+	-	-	-
		Muscle	+	-	+	-	-	-	-
0.53	96	Gill	+	-	+	-	-	+	-
		Liver	+	-	+	-	-	-	-
		Muscle	-	+	+	-	-	-	-
1.07	96	Gill	+	-	+	+	-	-	-
		Liver	+	-	+	-	-	-	-
		Muscle	+	-	+	-	-	-	-

L=Lesion; M= Malignancy; N= Necrosis; O = Inflammation; P=Pigment; Z= Cellular degeneration; R= Inclusion bodies, - = Completely absence, += Present, + + = Mild, + Severe. Treatment with negative signs indicated no histopathological changes were observed.

## DISCUSSION

The result obtained from this study showed that both the aqueous and ethanolic extract of *I. aquatica* had toxic effect on the juveniles of *O. niloticus* and the effect of their toxicity increases with time of exposure. The LC<sub>50</sub> values at 96 h of exposure of *O. niloticus* to aqueous and ethanolic extracts were 2.659 and 0.196 g/L, respectively.

The difference in the level of toxicity of the extracts could be as a result of the method of extraction used. In the case of aqueous extract, the alkaloids was extracted but the presence of water dilute it, hence reducing it potency, while the alkaloids of ethanolic extract obtained using soxhlet extractor and ethanol as extracting medium remains almost undiluted (Fafioye et al., (2008).

*O. niloticus* exhibited haphazard movement and aggressiveness (Abalaka and Auta, 2010) when placed in the bioassay tanks. Some attempted to

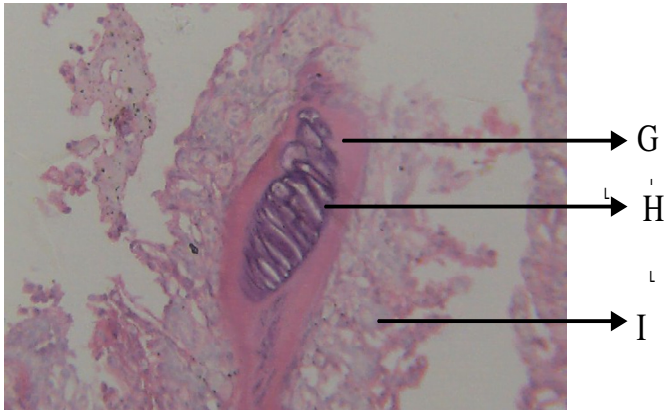
jump out of the tanks. This behaviour continued for a few hours after which their movement becomes normal and calm. Increased physical activity, convulsion, excess secretions of mucus, incessant gulping of air, erratic swimming, respiratory distress, paralysis, sudden quick movement, increase in opercula ventilation and prior to death darkening of fish were associated with *I. aquatica* toxicity in this study. This agreed with the findings of Alkahem et al. (1998) and Ayoola and Ajani (2007) on *O. niloticus* exposed to trichloroform and cypermethrin, respectively. Omitoyin et al. (1999) reported similar observation in *Sarotherodon galilaeus* fingerlings exposed to piscicidal plant extracts of *Tetrapleura tetraptera*.

The intensity of respiratory distress increased with increasing extracts concentrations but decreased with exposure period for both extracts while nervous abnormality increased with increase in concentrations and exposure period for both extracts. This agreed with the finding of Abalaka

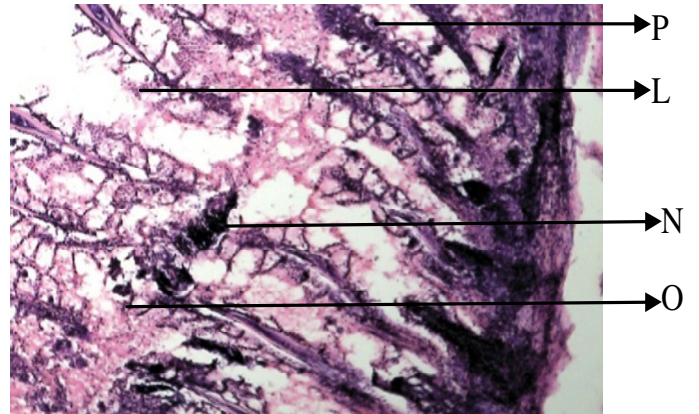
and Auta (2010). Extracts of *I. aquatica* probably poisoned the fish leading to pathological alterations in their tissues and organs (Gabriel et al., 2007) which eventually lead to the direct death of the tested organism. Indirect death could also be from changes in the physicochemical conditions of their immediate external environment (Ayoola, 2008; Olufayo, 2009). The observed respiratory distress may be due to decreased in the dissolved oxygen contents (Dede and Kaglo, 2001).

Warren (1977) had earlier reported that the introduction of a toxicant into an aquatic system might decrease the dissolve oxygen concentration, which will impair respiration leading to asphyxiation. Damages of the gills indicated that impairment in gaseous exchange efficiency of the gills Oedematous of the lamella and hyperplasia were observed and this is similar to the observation of Omoniyi et al. (2002).

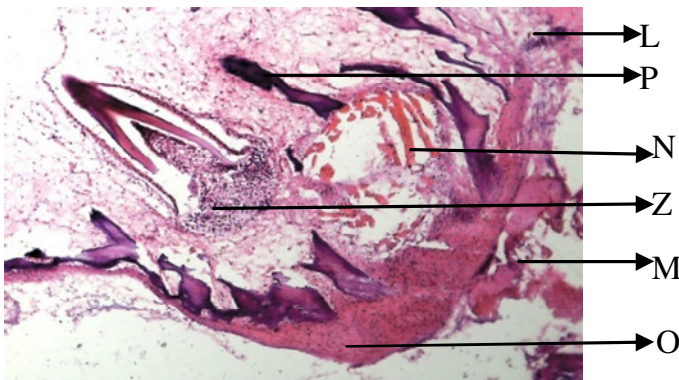
The histopathological examination of the gill,



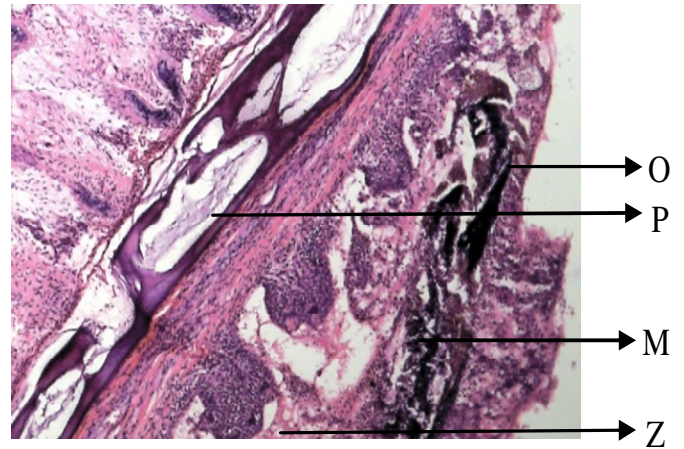
**Plate 1(A).** Gills of *O. niloticus*. The 96-h exposed in the control group showing the **G**, pseudo-brachial lamella, **H**, ceratobranchial bone of the arch and **I**, mucous epithelium lining on the membrane. No lesion, no necrosis, no pigments, no malignancy, no inflammation and inclusion bodies seen.



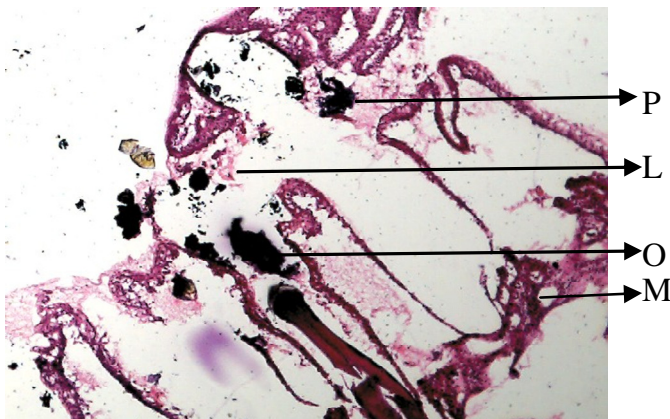
**Plate 1(D).** Gills of *O. niloticus*. The 96-h exposed at 2.5 g/L (aq. extract of *I. aquatica*) showing lesion, pigment, necrosis and inflammation.



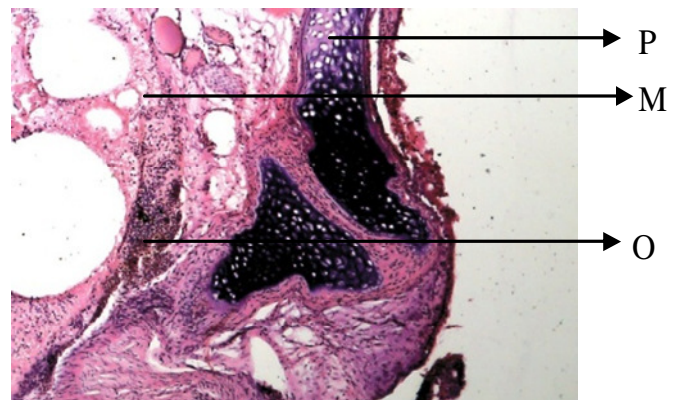
**Plate 1(B).** Gills of *O. niloticus*. The 96-h exposed at 0.5 g/L (aq. extract of *I. aquatica*) showing lesion, pigment, necrosis, cellular degeneration, malignancy and inflammation.



**Plate 1(E).** Gills of *O. niloticus*. The 96-h exposed at 3.5 g/L (aq. extract of *I. aquatica*) showing Inflammation, pigment, malignancy, cellular degeneration.

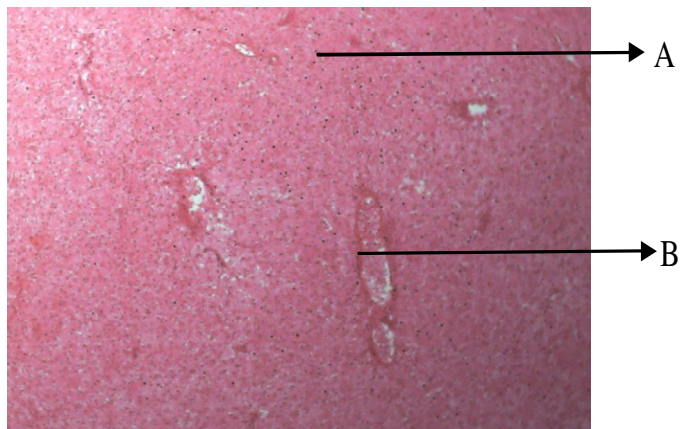


**Plate 1(C).** Gills of *O. niloticus*. The 96-h exposed at 1.5 g/L (aq. extract of *I. aquatica*) showing lesion, pigment, malignancy and inflammation.

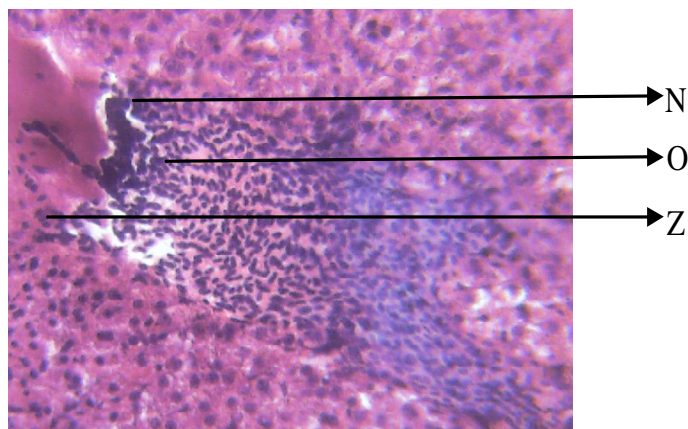


**Plate 1(F).** Gills of *O. niloticus*. The 96-h exposed at 4.5 g/L (aq. extract of *I. aquatica*) showing pigment, malignancy, cellular degeneration.

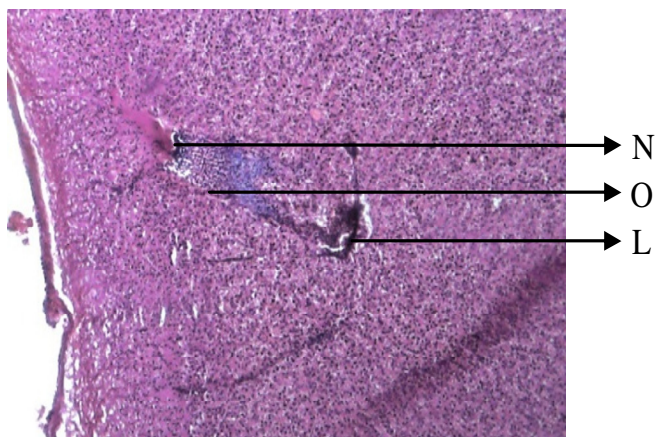




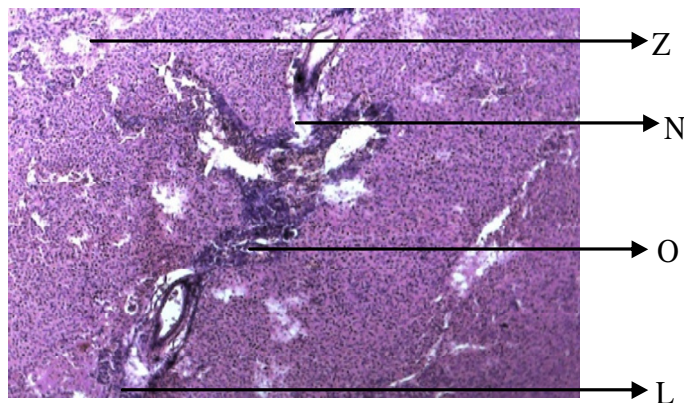
**Plate 2(A).** Liver of *O. niloticus*. The 96-h exposed in the control group cellular pattern, normal central vein, space of disse. No lesion, no necrosis, no pigments, no malignancy, no inflammation and inclusion bodies seen.



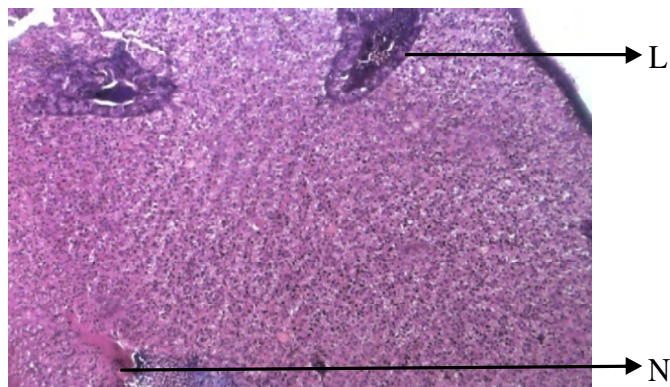
**Plate 2(D).** Liver of *O. niloticus*. The 96-h exposed at 2.5 g/L (aq.extract of *I.aquatica*) showing necrosis, inflammation and cellular degeneration.



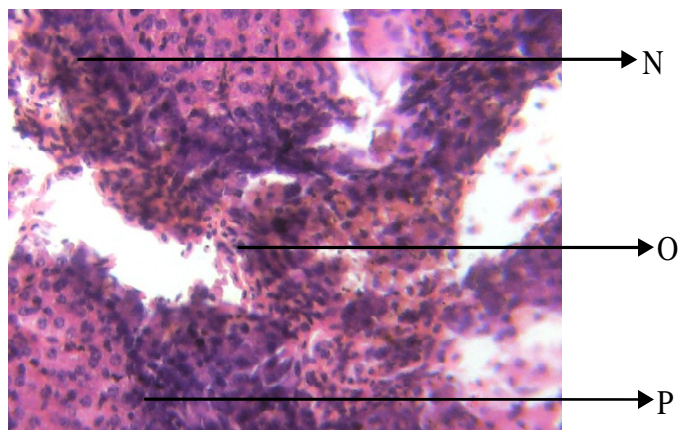
**Plate 2(B).** Liver of *O. niloticus*. The 96-h exposed at 0.5 g/L (aq.extract of *I.aquatica*) showing lesion, inflammation and necrosis.




**Plate 2(E).** Liver of *O. niloticus*. The 96-h exposed at 3.5 g/L (aq.extract of *I.aquatica*) showing cellular degeneration, necrosis, inflammation and lesion.



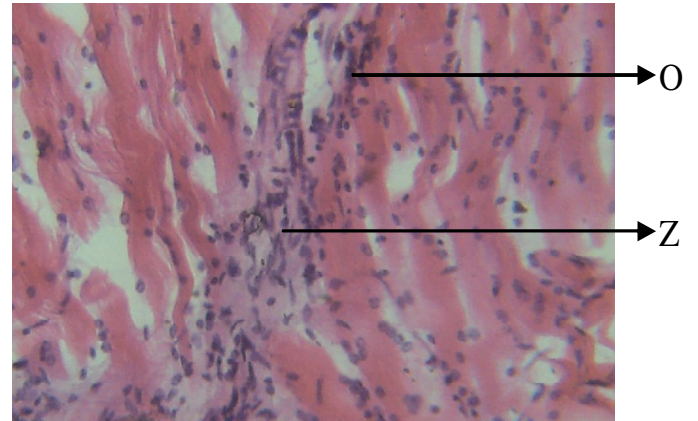
**Plate 2(C).** Liver of *O. niloticus*. The 96-h exposed at 1.5 g/L (aq.extract of *I.aquatica*) showing lesion and necrosis.



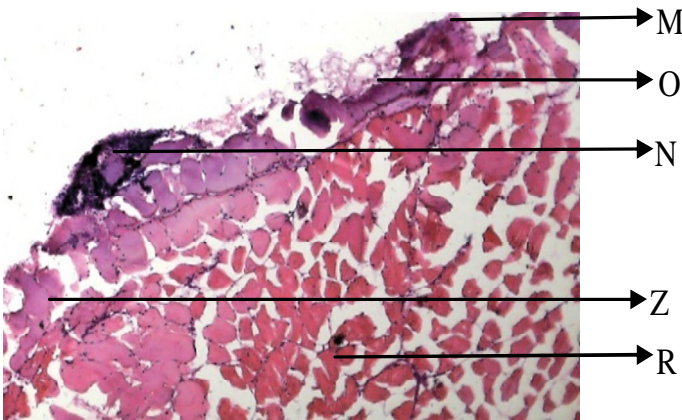
**Plate 2(F).** Liver of *O. niloticus*. The 96-h exposed at 4.5 g/L (aq.extract of *I.aquatica*) showing necrosis, pigment and inflammation.



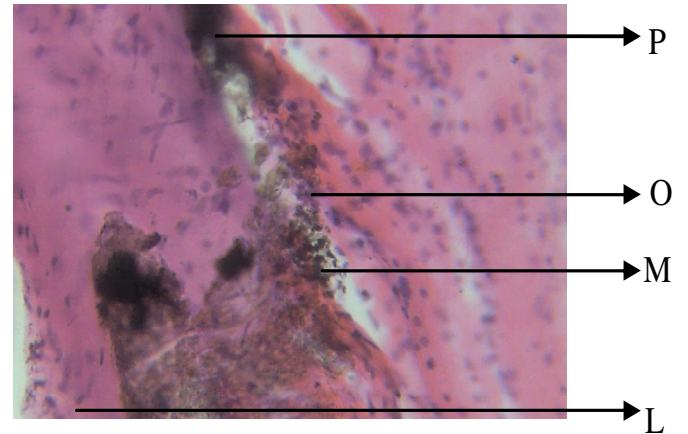
**Plate 3(A).** Muscle of *O. niloticus*. The 96-h exposed in the control group showing **A**, nucleus, **B**, muscle striation, **C**-microfilament, **D**, actin and myosin. No lesion, no necrosis, no pigments, no malignancy, no inflammation and inclusion



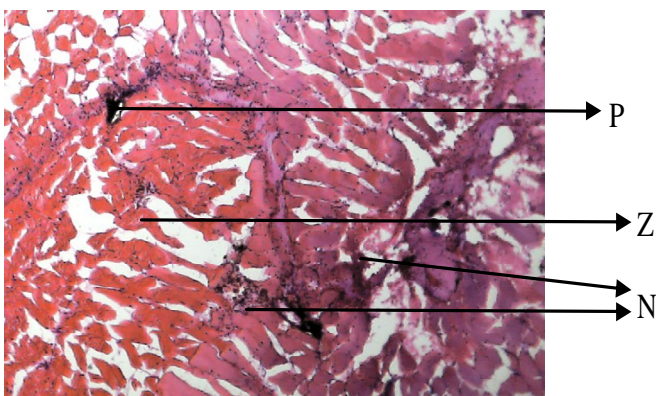
**Plate 3(D).** Muscle of *O. niloticus*. The 96-h exposed at 2.5 g/L (aq.extract of *I.aquatica*) showing inflammation and cellular degeneration.



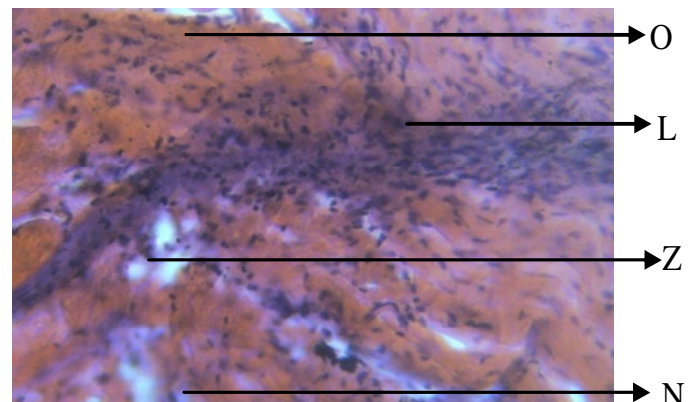
**Plate 3(B).** Muscles of *O. niloticus*. The 96-h exposed at 0.5 g/L (aq.extract of *I.aquatica*) showing malignancy, pigment, necrosis, cellular degeneration.



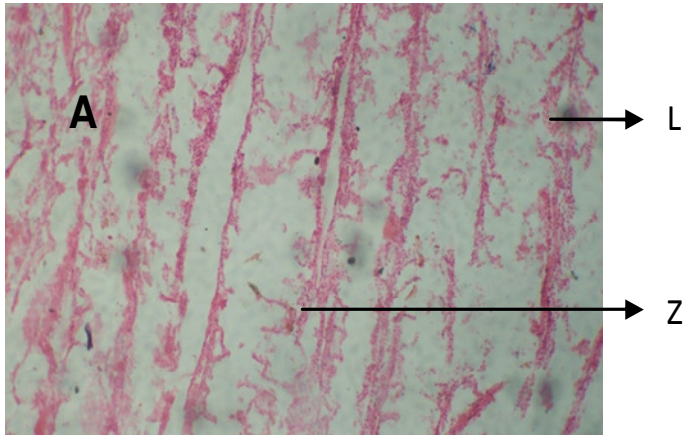
**Plate 3(E).** Muscle of *O. niloticus*. The 96-h exposed at 3.5 g/L (aq.extract of *I.aquatica*) showing pigment, inflammation, malignancy and lesion.



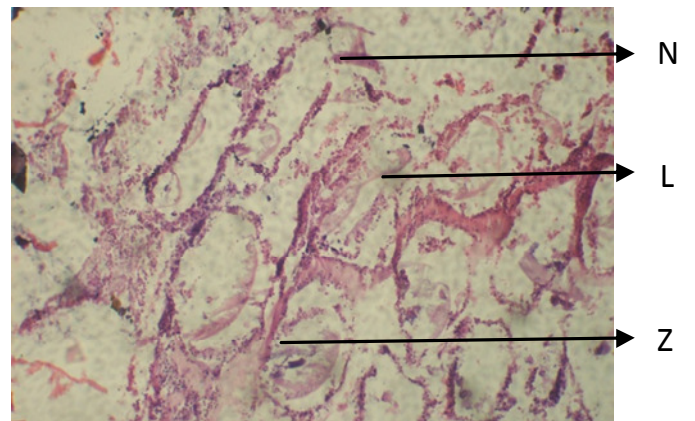
**Plate 3(C).** Muscle of *O. niloticus*. The 96-h exposed at 1.5g/L (aq.extract of *I.aquatica*) showing pigment, cellular degeneration and necrosis.



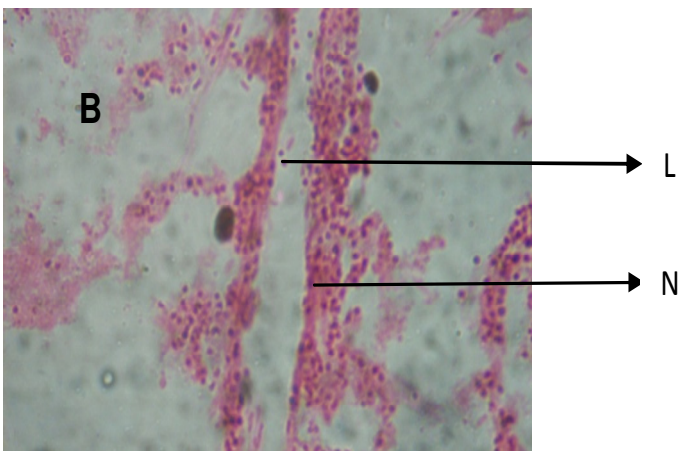
**Plate 3(F).** Muscle of *O. niloticus*. The 96-h exposed at 4.5 g/L (aq.extract of *I.aquatica*) showing inflammation, lesion, necrosis and cellular degeneration.



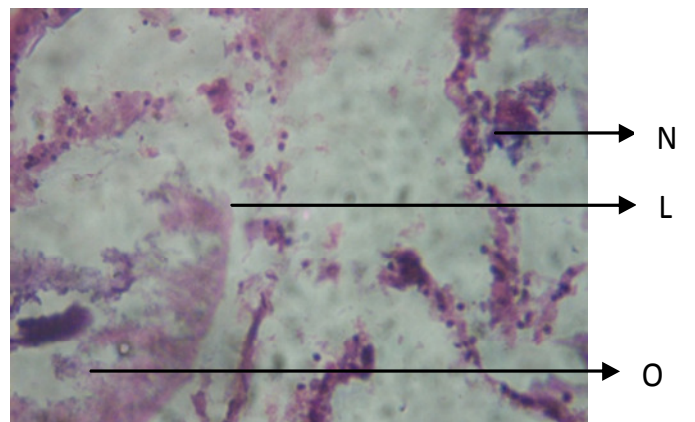
**Plate 4(A).** Gill of *O. niloticus*. The 96-h exposed at 0.11 g/L (et.extract of *I.aquatica*) showing lesion and cellular degeneration.



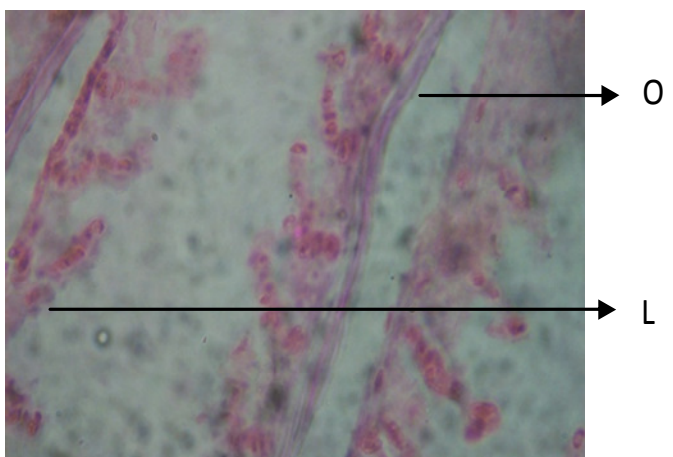
**Plate 4(D).** Gill of *O. niloticus*. The 96-h exposed at 0.53 g/L (et.extract of *I.aquatica*) showing Inflammation, lesion and cellular degeneration.



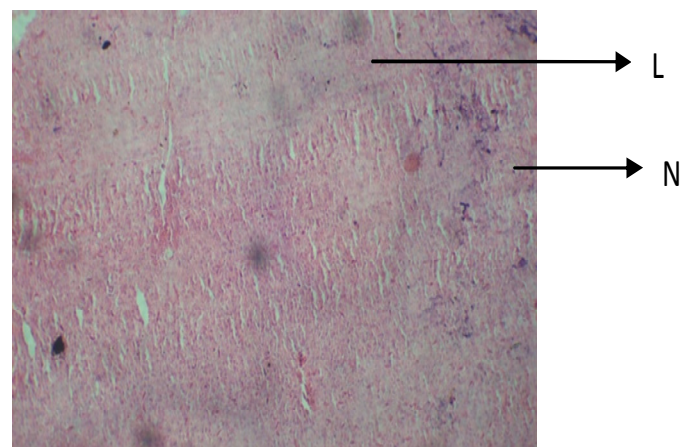
**Plate 4(B).** Gill of *O. niloticus*. The 96-h exposed at 0.21 g/L (et.extract of *I.aquatica*) showing lesion and necrosis.



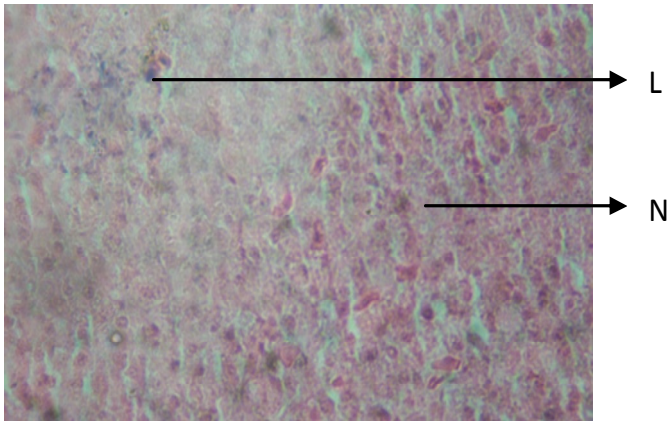
**Plate 4(E).** Gill of *O. niloticus*. The 96-h exposed at 1.07 g/L (et.extract of *I.aquatica*) showing Inflammation,lesion and cellular degeneration.



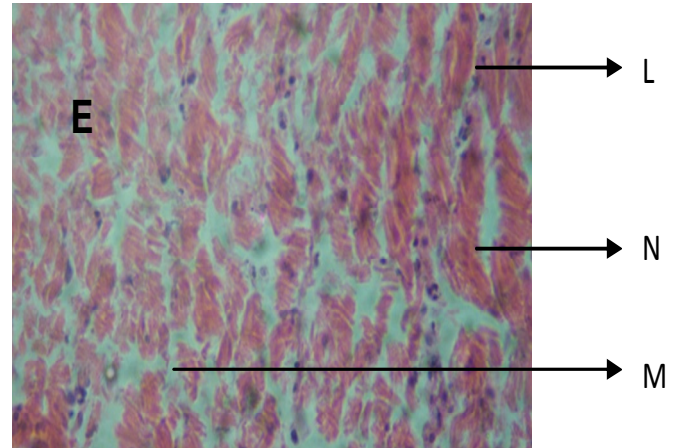
**Plate 4(c).** Gill of *O. niloticus*. The 96-h exposed at 0.43 g/L (et.extract of *I.aquatica*) showing Inflammation and lesion.



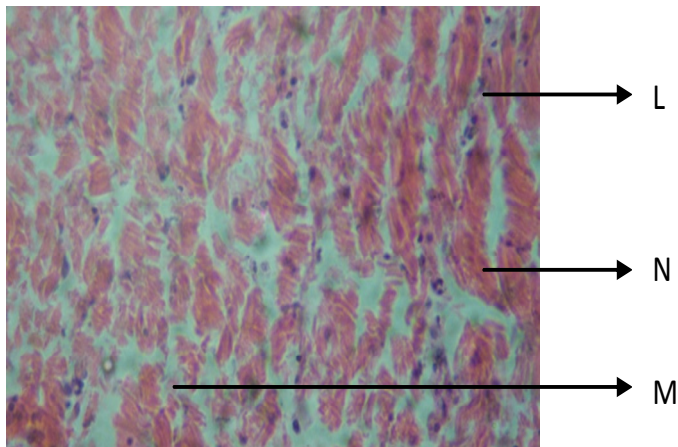
**Plate 5(A).** Liver of *O. niloticus*. The 96-h exposed at 0.11 g/L (et.extract of *I.aquatica*) showing lesion and necrosis.



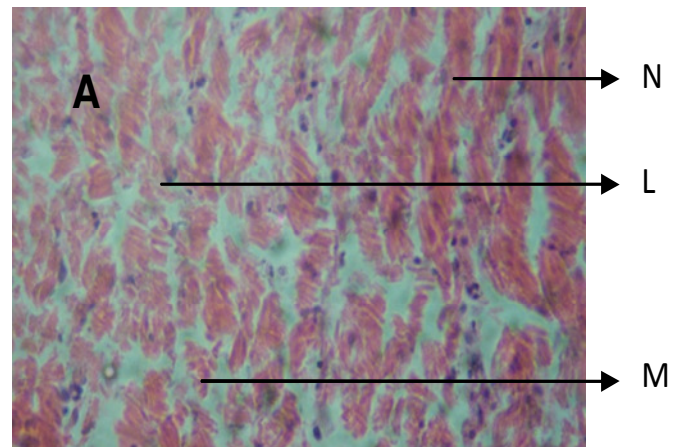
**Plate 5(B).** Liver of *O. niloticus*. The 96-h exposed at 0.21 g/L (et.extract of *I.aquatica*) showing lesion and necrosis.



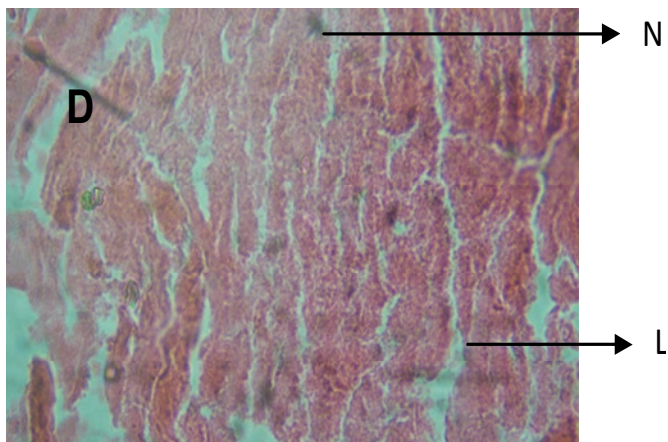
**Plate 5(E).** Liver of *O. niloticus*. The 96-h exposed at 1.07 g/L (et.extract of *I.aquatica*) showing necrosis and lesion.



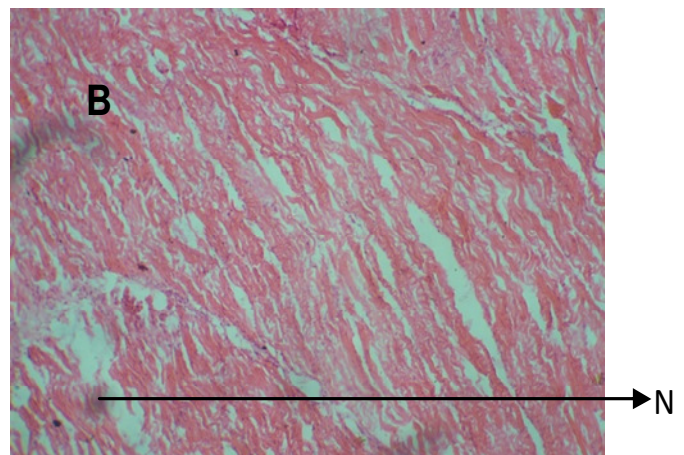
**Plate 5(C).** Liver of *O. niloticus*. The 96-h exposed at 0.43 g/L (et.extract of *I.aquatica*) showing malignancy, cellular degeneration and lesion.



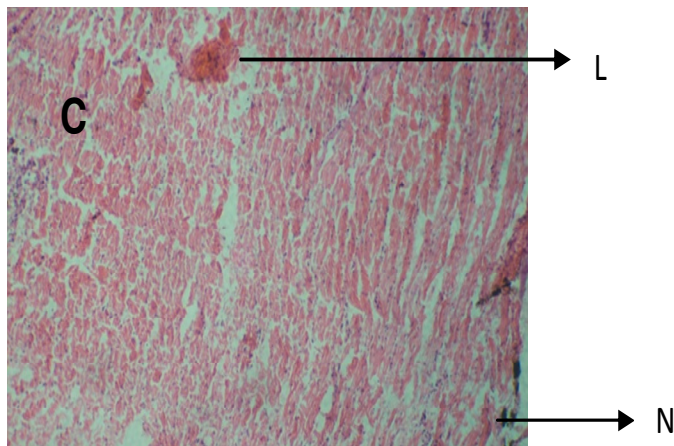
**Plate 6(A).** Muscle of *O. niloticus*. The 96-h exposed at 0.11 g/L (et.extract of *I.aquatica*) showing necrosis, lesion and malignancy



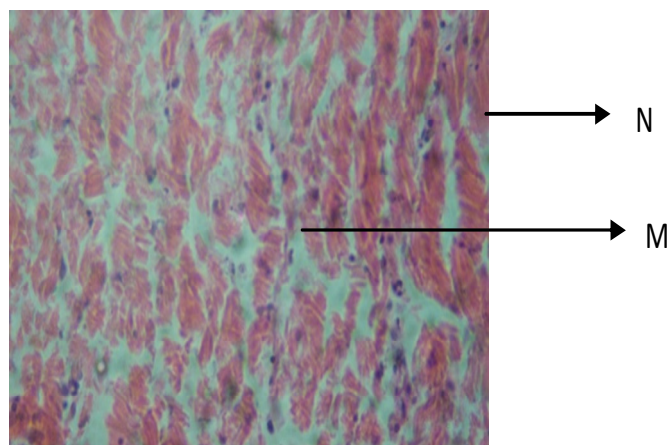
**Plate 5(D).** Liver of *O. niloticus*. The 96-h exposed at 0.53 g/L (et.extract of *I.aquatica*) showing necrosis and lesion.



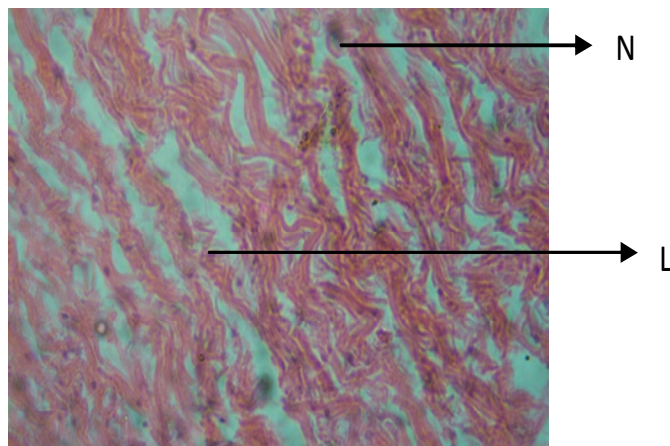
**Plate 6(B).** Muscle of *O. niloticus*. The 96-h exposed at 0.21 g/L (et.extract of *I.aquatica*) showing mild level of lesion.



**Plate 6(C).** Muscle of *O. niloticus*. The 96-h exposed at 0.43 g/L (et.extract of *I.aquatica*) showing lesion and necrosis.



**Plate 6(D).** Muscle of *O. niloticus*. The 96-h exposed at 0.53 g/L (aq.extract of *I.aquatica*) showing necrosis and malignancy.



**Plate 6(E).** Muscle of *O. niloticus*. The 96-h exposed at 1.07 g/L (et.extract of *I.aquatica*) showing lesion and necrosis.

liver, and muscle of the exposed fish indicated that the gill and liver were the organs most affected. This is similar to the observation of Rahman et al. (2002), Aguigwo (2002), Omitoyin et al. (2006) and Ayoola (2008). The liver of the exposed fish had vacuolated cells showing evidence of fatty degeneration. Necrosis of some portions of the liver tissue that were observed probably resulted from the excessive work required by the fish to get rid of the toxicant from its body during the process of detoxification and similar to the observation of Rahman et al. (2002). The inability of the fish to regenerate new liver cells may also have led to necrosis. Histopathological effects of extracts of *I. aquatica* on *O. niloticus* indicated lesion, pigment, necrosis, cellular degeneration, malignancy and inflammation on the gill after 96 h of exposure. This agrees with Fafioye et al. (2008) in which there were respiratory impairment and physiological dysfunction in *O. niloticus* on exposure to effluent from Chemistry Department Laboratories.

In this study, the treated liver showed lesion, necrosis, inflammation, malignancy, disorganized hepatic cord and cellular degeneration of the central vein. This is in line with Fafioye et al. (2005) in which aqueous and ethanolic extracts of *Parkia biglobosa* and *Raphia vinifera* exposed to *Clarias gariepinus* juveniles liver showed disorganized hepatic cords, haemosiderosis, coagulative necrosis and severe oedema occurred. At higher concentrations there were fatty degenerative necrosis and severe oedema.

Degeneration and necrosis of liver hepatocytes may be attributed to the cumulative effect of *I. aquatica* extracts and the increase of their concentrations in the hepatic tissue. This result agreed with Forlin et al. (1986), who stated that the liver has important detoxical role endogenous waste products as well as externally derived such as heavy metals.

The muscle of *O. niloticus* showed different levels of reactions ranging from lesion, necrosis, malignancy, inflammation, cellular degeneration and inclusion bodies to different concentration of *I. aquatica* extract.

## Conclusion

Generally, one could deduce from this research work that *I. aquatica* has piscicidal property and the introduction of *I. aquatica* into water bodies would threaten the life and existence of fish. Therefore, this plant can actually be use as a biological control in eradicating predators and unwanted organisms in the ponds by farmer instead of using agrochemicals.

## REFERENCES

- Abalaka SE, Auta J (2010). Toxic effects of Aqueous and Ethanolic extracts of *Parkia biglobosa* pods on *Clarias gariepinus* adults. World J. Biol. Res., 3(1): 9-17.

- Aguigwo JN (2002). The Toxic Effect of Cymbush Pesticide on growth and survival of African catfish, *Clarias gariepinus* (Burchell, 1822). J. Aquat. Sci. 17(2): 81-84.
- Ayoola SO (2008). Toxicity of Glyphosate herbicide on Nile tilapia (*Oreochromis niloticus*) juvenile. Afr. J. Agric. Res., 3(12): 825-834.
- Ayoola SO, Ajani EK (2007). Histopathological Effect of Cypermethrin on Juvenile Nile Tilapia (*Oreochromis niloticus*). Afr. J. Livest. Ext., 5: 1-13.
- Cook CDK (1990). Origin, autecology, and spread of some of the world's most troublesome aquatic weeds. . In: A.H. Pieterse and K.J. Murphy (eds.), pp. 31-38.
- Dede EB, Kaglo HD (2001). Aqua-toxicological effects of water soluble fractions (WSF) of diesel fuel on *O. niloticus* fingerlings. J. Appl. Sci. Environ. Manage., 5(1): 93-96.
- Fafioye OO, Adeogun, AO, Omoniyi IT (2008). Lethal Limits and Respiration in the Cichlid Fishes, *Tilapia zillii*, *Sarotherodon galilaeus*, *S. melanotheron* and *Oreochromis niloticus* Exposed to Effluent from Chemistry Department Laboratories. J. Appl. Sci. Environ. Manage., 12(1): 63-66.
- Fafioye OO, Fagade S O, Adebisi AA (2005). Toxicity of *Raphia vinifera*, P. beauv fruit extracts on biochemical composition of Nile Tilapia (*Oreochromis niloticus*, Trewavas). Biokemistri., 17(2): 137-142.
- Finney DJ (1980). Probit analysis. Cambridge University Press, Cambridge. Great Britain, 3: 124.
- Forlin L, Anderson T, Haux C, Olsson PE, Larsson A (1986). Physiological methods in fish toxicology, laboratory and field studies. In: Fish Physiology Recent Advances. Nilsson S, Holmgren S (Eds.). Croom Helm Ltd., London, U.K., pp. 158-169.
- Gabriel UU, Ezeri GNO, Amakiri EU (2007). Liver and kidney histopathology: Biomarkers of No. 1 fuel toxicosis in African catfish, *Clarias gariepinus*. J. Anim. Vet. Adv., 6(3): 379-384.
- Jennes J (1967). The use of plants as fish poison within the Kanji basin. In: Reed W (Ed). Fish and fisheries of Northern Nigeria. Ministry of Agriculture of Nigeria, p. 226.
- Koesomadinata S (1980). Pesticide as a major constraint in integrated Agriculture- aquaculture farming system. In: R. S. V. Pullin and Z. H., pp. 45-51.
- Murthy AS (1986). Toxicity of pesticides to fish. CRC Press Inc. Boca Raton, FL., USA., p. 143.
- Odiete WO (1999). Environmental Physiology of Animals and Pollution Diversified Resources Ltd Lagos. p. 261.
- Olufayo MO (2009). Haematological characteristics of *Clarias gariepinus* (Burchell 1822) Juveniles exposed to Derris elliptia root powder. Afr. J. Food Agric. Nutr. Dev., 9(3): 920-932.
- Omitoyin BO, Ajani EK Adesina BT, Okuagu, CNF (2006). Toxicity of Lindane (Gamma Hexachloro - CycloHexane) to *Clarias gariepinus* (Burchell 1822). World J. Zool., 1(1): 57-63.
- Omitoyin BO, Ogunsami AO, Adesina BT (1999). Studies on acute toxicity of Piscicidal plant extracts (*Tetrapleura tetraptera*) on tilapia (*Sarotherodon galilaeus*) fingerlings. Trop. J. Anim. Sci., 2(2): 191-197.
- Omoniyi IA, Agbon O, Sodunke SA (2002). Effects of lethal and sub-lethal concentrations of Tobacco (*Nicotiana tobaccum*), Leaf dust extraction on weight and haematological changes in *Clarias gariepinus* (Burchell). J. Appl. Sci. Environ. Manage., 6: 37-41.
- Rahman MZ, Hossain Z, Mellah MFA, Ahmed GU (2002). Effect of diazinon 60EC on *Anabus testudineus*, *Channa punctatus* and *Barbades gommonotus* Naga. The ICLARM Quart., 25: 8-11.
- Tumanda M (1980). Effects of rotenone containing Derris root extracts on the mortality of some predator fishes of pond cultured prawns under different water temperature salinity combinations. M.Sc thesis. University of San Carlos, Cebu City, Philippines, p. 89.
- Wang D, Huffman JB (1991). Botanochemicals supplements to petrochemicals. Econ. Bot., 35(4): 369-382.
- Warren D (1977). Biology and water pollution control. Saunder, W.B. Company, Philadelphia, First Edition, pp. 24-39.