
Two-phase carcinogenesis in hamster buccal pouch

Onatolu Odukoya, B.D.S., and Gerald Shklar, D.D.S., M.S., Boston, Mass.

DEPARTMENT OF ORAL MEDICINE AND ORAL PATHOLOGY, HARVARD SCHOOL OF DENTAL MEDICINE

A two-phase mechanism of chemical carcinogenesis in hamster buccal pouch has been demonstrated. Painting of buccal pouches three times weekly with a 0.1 percent solution of 7,12-dimethylbenz(a)anthracene (DMBA) in mineral oil for 10 weeks resulted in no visible tumors nor any microscopic evidence of dysplasia after the animals had been maintained for a 20 week period (Group 1 animals). Painting with 0.1 percent DMBA for 10 weeks, no treatment for a following 6 week period, and painting with 0.5 percent DMBA for a subsequent 4 weeks resulted in epidermoid carcinomas (Group 2 animals). Painting with 0.5 percent DMBA for 4 weeks in animals without prior treatment resulted in no tumors (Group 3 animals). It is postulated that the early treatment in Group 2 may serve for initiation and the later treatment for promotion.

The hamster buccal pouch has served as the major oral cancer model system since it was first demonstrated by Salley¹ that epidermoid carcinomas could be induced by the continued application of solutions of chemical carcinogens such as dimethylbenzanthracene. The model has subsequently been refined by Morris², Silverman and Shklar,³ Sanlis, Shklar, and Chauncey,⁴ and Shklar.^{5,6} It is now established that thrice-weekly application of 0.5 percent solution of 7,12-dimethylbenz(a)anthracene (DMBA) in heavy mineral oil to the buccal pouch mucosa produces, histologically, areas of hyperkeratosis and dysplasia at 6 to 8 weeks, early epidermoid carcinoma at 8 to 10 weeks, and, finally, invasive carcinoma at 10 to 12 weeks. Usually the procedure of the carcinogen application is continued until the termination of the experiment. Eisenberg⁷ has, however, demonstrated that the alterations from normal have occurred by 10 to 12 weeks and are irreversible despite cessation of the DMBA applications.

Berenblum,⁸ in early studies on mouse skin carcinogenesis, suggested that carcinogenesis consists of three phases: the initiation stage, the promotion stage, and a specific stage of metacarcinogenesis. The latter stage was believed to be concerned with conversion of the benign skin papillomas to carcinomas. Subsequent work by Berenblum and Shubik^{9,11} showed that carcinogenesis is, in fact, a two-stage mechanism consisting of a specific and irreversible initiating phase in which normal cells are converted to latent tumor cells that lie dormant until stimulated in the promoting phase to become morphologic tumors. The promoting phase can be brought about

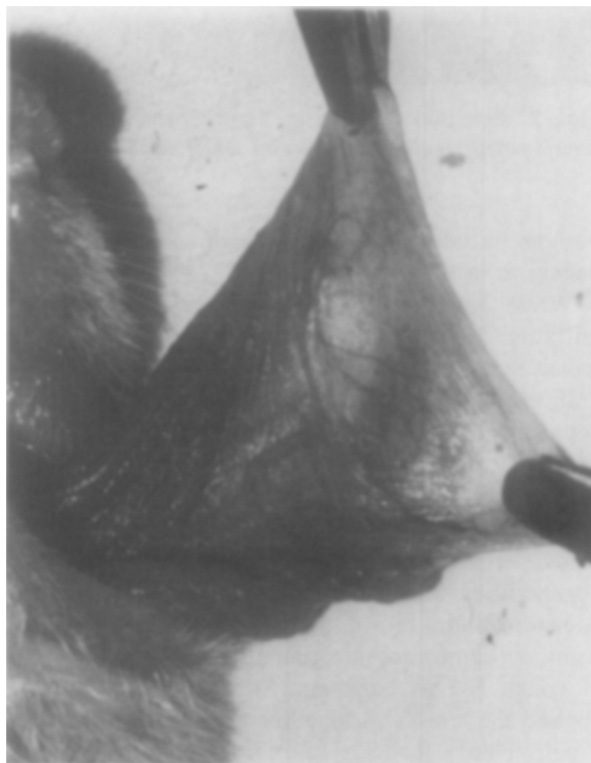


Fig. 1. Left buccal pouch in Group 1 animal showing absence of pathology.

by the use of noncarcinogenic agents such as croton oil. Ritchie and Saffiotti¹² introduced another dimension to the application of the two-stage mechanism of carcinogenesis when they demonstrated that oral administration of 2-acetyl-aminofluorene acted as

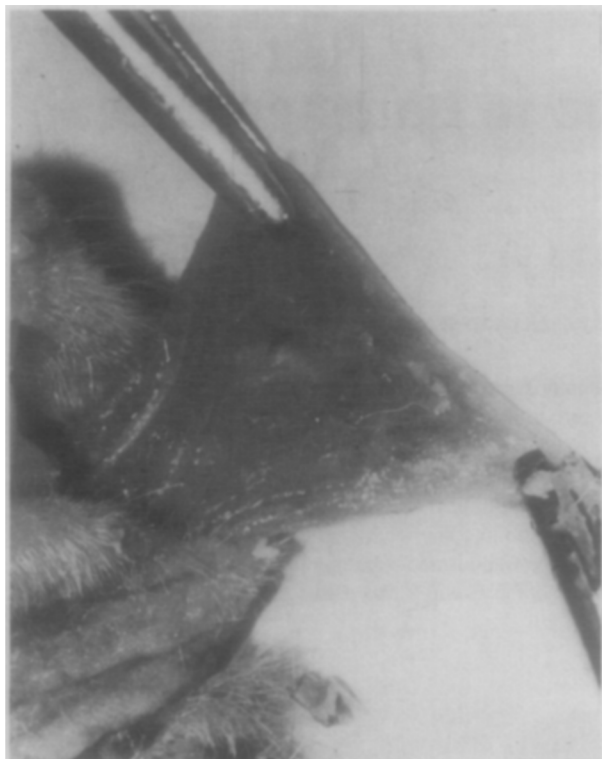


Fig. 2. Left buccal pouch in Group 3 animal showing several small plaque-like areas and some erosion.



Fig. 3. Left buccal pouch in Group 2 animals showing a number of small tumors and two larger lesions.

both an initiator and a promoter of epidermal carcinogenesis in their model.

While most of the studies dealing with tumor initiation and promotion have been carried out on mouse skin, very little related work has been done on oral mucosa. Renstrup, Smulow, and Glickman¹³ demonstrated that mechanical irritation appeared to hasten the development of hamster pouch carcinoma induced with carcinogenic chemicals. Silberman and Shklar,³ working with the hamster buccal pouch model, demonstrated enhancement of DMBA carcinogenesis by croton oil in a series of older Syrian hamsters, and a retardation of DMBA carcinogenesis by the same concentration of croton oil in a series of young Syrian hamsters. Silberman and Shklar applied the croton oil together with DMBA in their experimental model. Recently, Freedman and Shklar¹⁴ demonstrated enhancement of DMBA oral carcinogenesis by the systemic administration of alcohol.

In attempting to apply the two-stage concept of carcinogenesis to the hamster buccal pouch model system, we designed a procedure to facilitate the study of initiation and promotion by the same chemical carcinogen, DMBA. Our procedure is somewhat similar to that described by Ritchie and

Saffiotti.¹² While we used 0.1 percent 7,12-dimethylbenz(a)anthracene as initiator and 0.5 percent DMBA as promoter, Ritchie and Saffiotti carried out several experiments to demonstrate their concept. In one experiment to show that 2-acetylaminofluorene is an initiator, they used croton oil as a promoter. In another experiment to demonstrate 2-acetylaminofluorene as a promoter, they used DMBA as an initiator.

MATERIALS AND METHODS

Sixty male and female young adult golden Syrian hamsters (*Mesocricetus auratus*) served as experimental animals and were divided into three equal groups, with ten male and ten female animals in each group. The hamsters were random bred (Lakeview strain LVG) and were fed standard Purina laboratory pellets and water *ad libitum*.

Group 1. The left buccal pouch was painted three times weekly with a 0.1 percent solution of DMBA in heavy mineral oil USP with No. 3 sable brush. Painting was stopped after 10 weeks and the animals remained untreated for the next 10 weeks.

Group 2. The left buccal pouch was painted three times weekly with a 0.1 percent solution of DMBA in heavy mineral oil. Painting was stopped after 10

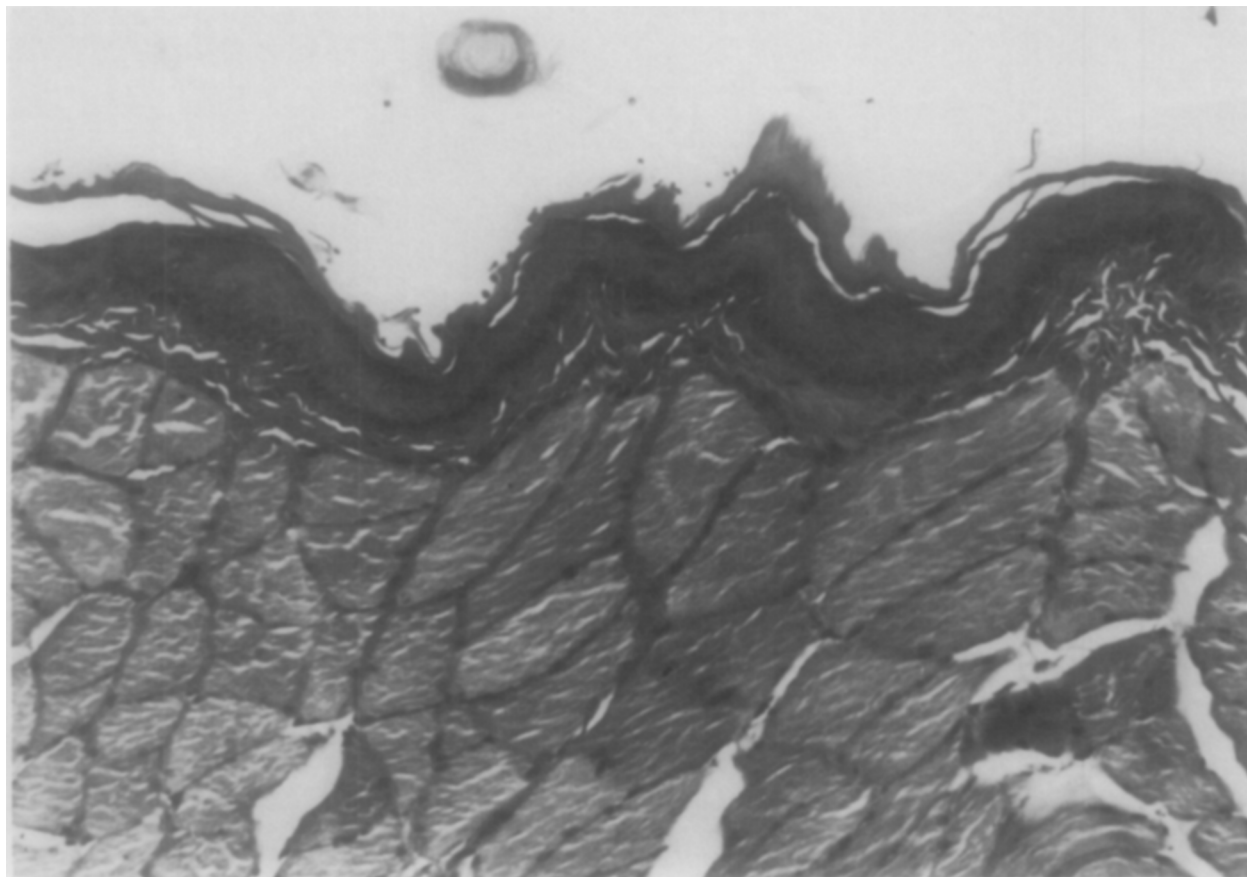


Fig. 4. Left buccal pouch mucosa in Group 1 animal showing normal epithelium with slight hyperkeratosis. (Hematoxylin and eosin; $\times 200$.)

weeks, and the animals were untreated for the next 6 weeks. From weeks 16 to 20, the left buccal pouches were painted with a solution of 0.5 percent DMBA in heavy mineral oil.

Group 3. Animals were untreated for the first 16 weeks. From weeks 16 to 20 the left buccal pouches were painted with a solution of 0.5 percent DMBA in heavy mineral oil.

At the termination of the 20-week experimental period, all animals were killed with carbon dioxide. Both left and right buccal pouches were examined grossly for evidence of pathosis and photographed. Tumors, if present, were measured and counted in each animal and recorded. The left and right buccal pouches were excised, fixed in 10 percent formalin, sectioned in paraffin, and stained with hematoxylin and eosin for microscopic study.

RESULTS

Gross observations

The buccal pouches of Group 1 animals appeared normal, and there were no tumors (Fig. 1). The

buccal pouches of Group 3 animals demonstrated some evidence of inflammation, but no tumors were observed (Fig. 2). In the Group 2 animals, all the left buccal pouches demonstrated some evidence of gross pathologic change. There were small tumors and patches of white roughened surface in all animals (Fig. 3). The tumors ranged in size from 0.5 to 2.5 mm., and there were from two to seven tumors per pouch.

Microscopic observations

The buccal pouches in Group 1 animals were essentially normal. The left experimental and right control pouches could not be distinguished from one another microscopically (Fig. 4).

The left buccal pouches in Group 3 animals demonstrated scattered areas of hyperkeratosis and dysplasia (Fig. 5). There were also areas of chronic inflammation and some foci of ulceration and acute purulent inflammation. There was no evidence of carcinoma. The right buccal pouches were normal.

The left buccal pouches in the Group 2 animals

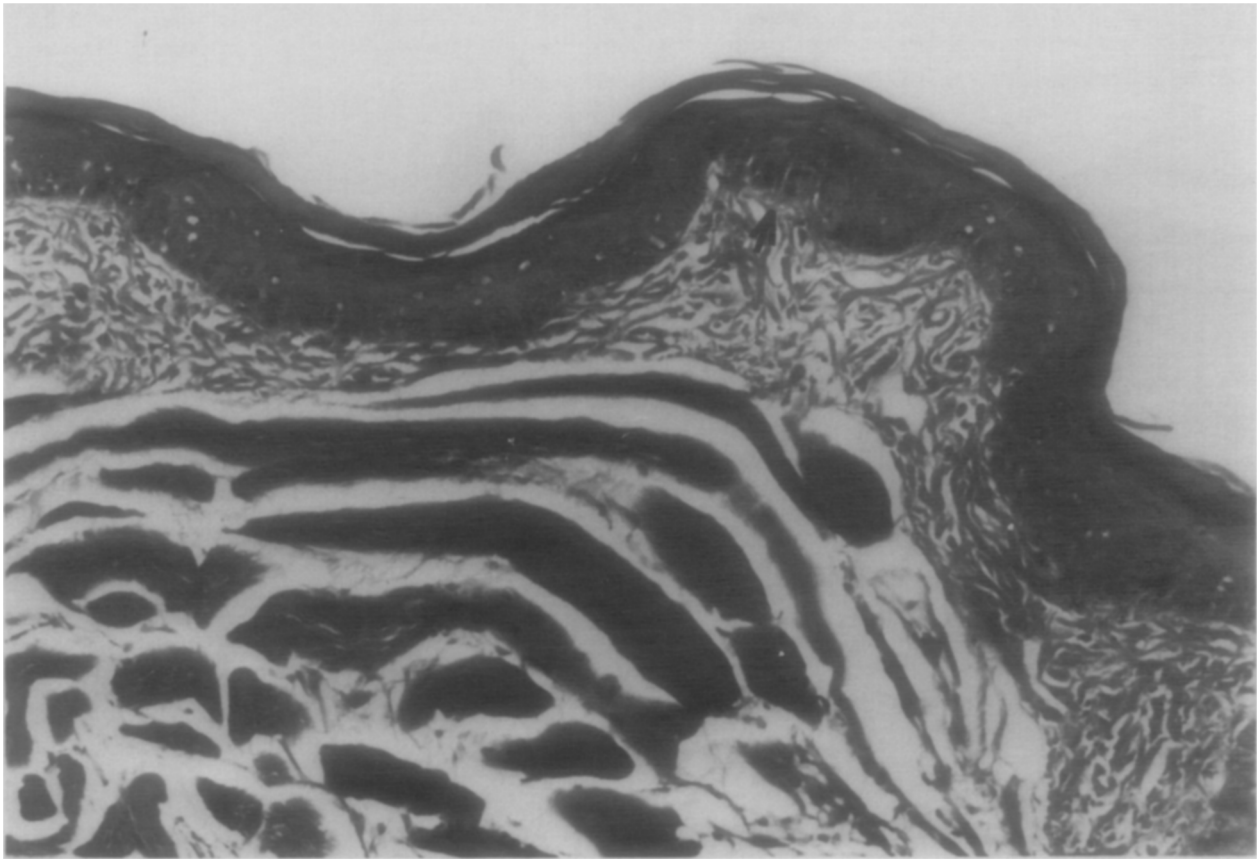


Fig. 5. Left buccal pouch mucosa in Group 3 animal showing slight hyperkeratosis and some evidence of dysplasia (arrow). (Hematoxylin and eosin; $\times 200$.)

demonstrated hyperkeratosis, numerous areas of dysplasia and carcinoma in situ, and occasional gross papillary epidermoid carcinomas (Fig. 6). The carcinomas were well-differentiated lesions with obvious keratin formation and relatively minimal invasion into underlying connective tissue.

DISCUSSION

The results are of considerable interest in that they demonstrate that the initial application for 10 weeks of a low dosage of chemical carcinogen did not result in neoplasia that could be seen either grossly or microscopically. Some alteration in the epithelial cells obviously occurred, however, since they had been sensitized to further application of carcinogen at a later time. The second series of carcinogen applications, after a 6-week delay, resulted in the rapid appearance of dysplasia and epidermoid carcinomas, even though this 4-week dose of topical carcinogen was insufficient to induce tumors by itself. This was demonstrated in the Group 3 animals.

This study demonstrates the probable existence of an initiation phase by a low dosage of carcinogen. In this initiation phase some cellular alteration has presumably occurred but was not visible with the standard light microscope. This presumed cellular change did not develop into neoplasia during the subsequent 10 weeks of the experiment. Since a second course of DMBA induced tumors so rapidly in the previously treated animals, even though the DMBA was insufficient to induce tumors in untreated animals, it can be presumed that it acted as a promoter, thus confirming the original concept of Berenblum of two phases in chemical carcinogenesis.

Since DMBA was used for both initiation and promotion in our experiment, it could be argued that the development of carcinomas in the Group 2 animals represented a summation effect of two episodes of subeffective dosages. Further studies are planned so that noncarcinogens such as phorbol ester or benzoyl peroxide will be used for promotion, rather than DMBA.

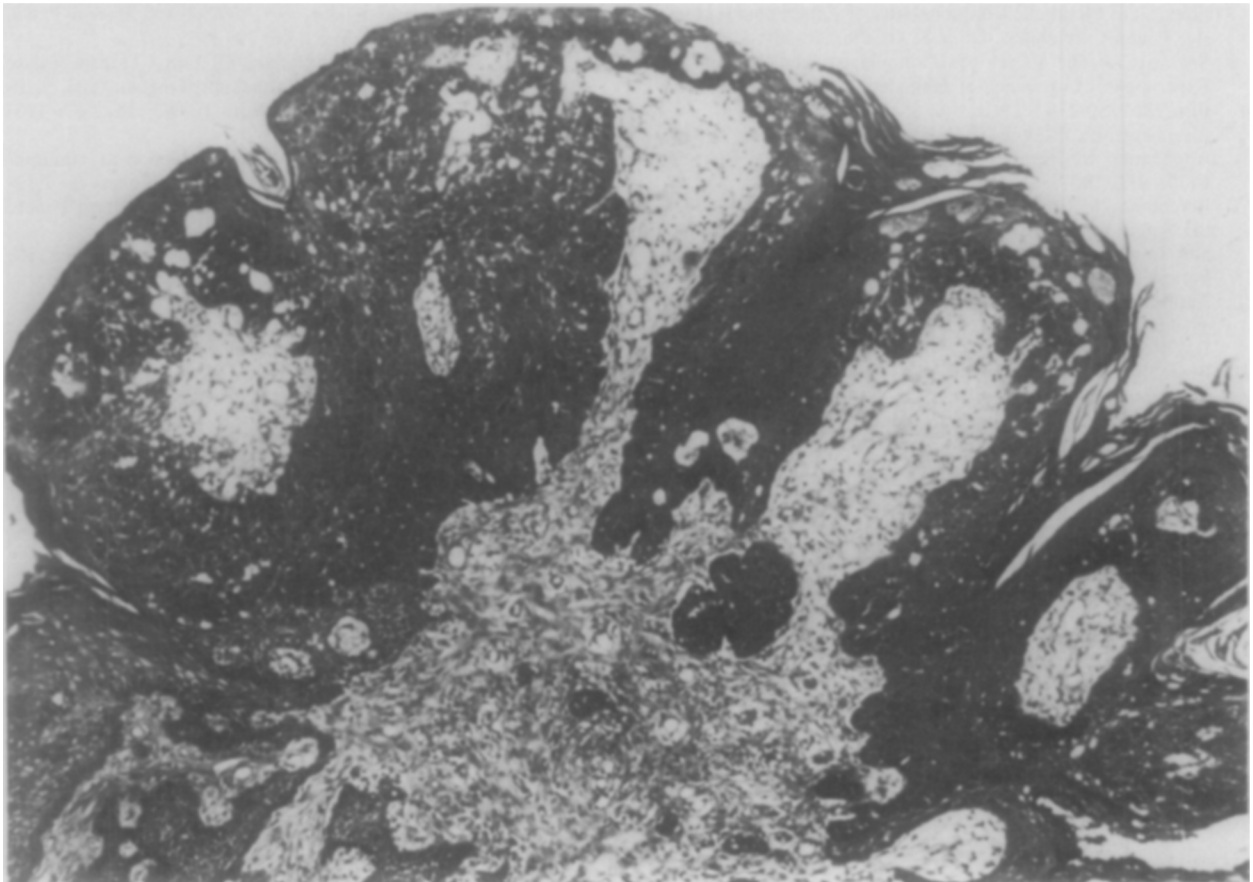


Fig. 6. Epidermoid carcinoma of left buccal pouch in Group 2 animal. The tumor is papillary and well differentiated. (Hematoxylin and eosin; $\times 100$.)

The demonstration that some type of cellular alteration must have occurred during the first 10 weeks of application of 0.1 percent DMBA is consistent with several recent observations, and further studies should be carried out to discern any histochemical or ultrastructural changes. Studies in cell kinetics may also offer some information on initiation.

Solt¹⁵ has found that gamma-glutamyl transpeptidase (GGT) activity can be demonstrated in the hamster buccal pouch treated with DMBA for 4 weeks. Solt and Shklar¹⁶ have further demonstrated that single cells and small clusters of GGT-positive cells can be demonstrated after one application of DMBA to the hamster buccal pouch. These GGT-positive cells may represent transformed cells that eventually could be further stimulated or promoted to develop into carcinomas. Subeffective dosages of chemical carcinogen also affect cells other than epithelial cells of the hamster buccal pouch. Schwartz and co-workers¹⁷ have shown that 5 weeks of painting twice weekly with a 0.5 percent solution of DMBA in mineral oil resulted in a significant

alteration in Langerhans cells, with diminution in number and alteration in morphology. Since the Langerhans cells have Fc-IgG receptors, C₃ receptors, Ia antigens in mice, and HLA-DR antigens (Ia-like) in human subjects, they may function as macrophages,^{18,19} and their diminution may play a role in facilitating carcinogenesis by an alteration of local immune reactivity.

Further studies on the early changes in buccal pouch carcinogenesis should reveal significant information concerning fundamental mechanisms of tumor initiation and promotion.

REFERENCES

1. Salley, J. J.: Experimental Carcinogenesis in the Cheek Pouch of the Syrian Hamster, *J. Dent. Res.* **33**: 253-262, 1954.
2. Morris, A. L.: Factors Influencing Experimental Carcinogenesis in the Hamster Cheek Pouch, *J. Dent. Res.* **40**: 3-15, 1951.
3. Silverman, S., and Shklar, G.: The Effect of a Carcinogen (DMBA) Applied to the Hamster's Buccal Pouch in Combination with Croton Oil, *ORAL SURG.* **16**: 1344-1365, 1963.
4. Santis, H., Shklar, G., and Chauncey, H. H.: Histochemistry of Experimentally Induced Leukoplakia and Carcinoma of the Hamster Buccal Pouch, *ORAL SURG.* **17**: 207-218, 1964.

5. Shklar, G.: Metabolic Characteristics of Experimental Hamster Pouch Carcinomas. *ORAL SURG.* **20**: 336-339, 1965.
6. Shklar, G.: The Effect of Manipulation and Incision on Experimental Carcinoma of Hamster Buccal Pouch. *Cancer Res.* **28**: 2180-2182, 1968.
7. Eisenberg, E.: Neoplasia Following Cessation of DMBA Application to Hamster Buccal Pouch. *J. Dent. Res.* **56**: 1430-1431, 1977.
8. Berenblum, I.: The Mechanism of Carcinogenesis. A Study of the Significance of Cocarcinogenesis and Related Phenomenon. *Cancer Res.* **1**: 807-814, 1941.
9. Berenblum, I., and Shubik, P.: The Role of Croton Oil Applications Associated With a Single Painting of a Carcinogen in Tumor Induction of the Mouse's Skin. *Br. J. Cancer* **1**: 379-382, 1947.
10. Berenblum, I., and Shubik, P.: A New Qualitative Approach to the Study of the Stages of Chemical Carcinogenesis in the Mouse's Skin. *Br. J. Cancer* **1**: 383-391, 1947.
11. Berenblum, I., and Shubik, P.: An Experimental Study of the Initiating Stage of Carcinogenesis and Re-examination of the Somatic Cell Mutation Theory of Cancer. *Br. J. Cancer* **3**: 109-118, 1949.
12. Ritchie, A. C., and Saffiotti, U.: Orally Administered 2-Acetylaminofluorene as an Initiator and as a Promoter of Epidermal Carcinogenesis in the Mouse. *Cancer Res.* **15**: 84-93, 1955.
13. Renstrup, G., Smulow, J., and Glickman, I.: Effect of Chronic Mechanical Irritation on Chemically Induced Carcinogenesis in the Hamster Cheek Pouch. *J. Am. Dent. Assoc.* **64**: 770-777, 1962.
14. Freedman, A., and Shklar, G.: Alcohol and Buccal Pouch Carcinogenesis. *ORAL SURG.* **46**: 794-802, 1978.
15. Solt, D. B.: Localization of Gamma-Glutamyl Transpeptidase in Hamster Buccal Pouch Epithelium Treated With 7,12-dimethylbenz(a)anthracene. *J. Natl. Cancer Inst.* **67**: 193-200, 1981.
16. Solt, D. B., and Shklar, G.: Rapid Induction of Gamma-Glutamyl Transpeptidase-rich Epithelial Clones in 7,12-dimethylbenz(a)anthracene Treated Hamster Buccal Pouch. *Cancer Res.* **42**: 285-295, 1982.
17. Schwartz, J., Solt, D. B., Pappo, J., and Weichselbaum, R.: Distribution of Langerhans Cells in Normal and Carcinogen-Treated Mucosa of Buccal Pouches of Hamsters. *J. Dermatol. Surg. Oncol.* **7**: 1005-1010, 1981.
18. Rowden, G., Phillips, T. M., and Delovitch, T. L.: Expression of Ia Antigen by Murine Keratinizing Epithelial Langerhans Cells. *Immunogenetics* **7**: 465-478, 1978.
19. Stingl, G., Katz, S. I., Shevach, E. M., Rosenthal, A. S., and Green, I.: Analogous Functions of Macrophages and Langerhans Cells in the Initiation of the Immune Response. *J. Invest. Dermatol.* **71**: 59-64, 1978.

Reprint requests to:

Dr. Gerald Shklar
Department of Oral Medicine and Oral Pathology
Harvard School of Dental Medicine
188 Longwood Ave.
Boston, Mass. 02115