

# Dysphagia due to Diabetic Autonomic Neuropathy

A. O. FASANMADE\*, A. E. OHWOVORIOLE, T.O. JOHNSON

Department Of Medicine,  
Lagos University Teaching Hospital,  
PMB 12003, Lagos

## SUMMARY:

Diabetic autonomic neuropathy (DAN), affects several systems with varying manifestations. The gastrointestinal system is one of the major targets for damage in long standing diabetes. Clinical manifestation of autonomic neuropathy involving the gastrointestinal system may be obvious or pose diagnostic problems when the diagnosis is not suspected. Here we present a case of autonomic neuropathy involving the oesophagus with the presentation of progressive dysphagia mimicking a neoplasm. *Niger Med J.* 1994; 27 (2 &3): 65-67.

**KEYWORDS:** *Diabetes Mellitus; Autonomic Neuropathy; Dysphagia.*

## INTRODUCTION

Diabetes mellitus which is a common metabolic disease has a wide and varying impact on the different systems which manifest with time as the chronic complications of the disease such as neuropathy, nephropathy and retinopathy. Diabetic neuropathy is the commonest of these complications and is seen in 10 – 100% of non-insulin-dependent diabetics at the time of diagnosis (1). DAN is common in long standing diabetes but exact prevalence remains difficult to determine, due to the protean nature of the condition. The commonest symptoms are constipation, diarrhoea, post prandial fullness and bloating (2,3). Dysphagia is a less commonly reported symptom. When it occurs, it is often due to DAN. In Caucasians, 27% of persons with diabetes were found to have this symptom (3). In a similar clinical study of Nigerians the frequency was found to be low at 2% (4). Subclinical disorders of oesophageal motility are, however, much more common as demonstrated by some other studies (2,3,5). This report describes a patient who presented with this symptom which was initially thought to be due to oesophageal carcinoma.

## CASE REPORT

A 61-year old man, with non-insulin dependent diabetes of 15 years' duration was seen at the Diabetes Clinic of the Lagos University Teaching Hospital. His principal complaints were abnormal sensations in the hands and feet of four years' duration. There was also difficulty in swallowing both solids and liquids of six months' duration. He had no associated chest pain or significant weight loss. Systemic review revealed the presence of constipation, impotence, and postural dizziness.

On physical examination he weighed 77 kg and was 1.73 metres tall (body mass index of 26). His arterial pulse rate was 82/minute and regular. All peripheral pulses were palpable and of normal character. The blood pressure measured  $150/80$  mm of Hg in the supine position and  $120/70$  mm Hg while erect. His pupils were of normal size and shape and reacted promptly to light stimuli. Fundoscopy revealed hard exudates and microaneurysms. Urinalysis showed glycosuria of 100 mg/dl (5.5 mmol/L) but no albuminuria using Albustix® reagent strips. Differential diagnosis considered at this stage included carcinoma of the oesophagus, achalasia, hiatus hernia and pharyngeal pouch.

Laboratory investigations showed a fasting blood sugar of 108 mg/dl (6.0 mmol/L) and a 2-hour post prandial level of 216 mg/dl (12 mmol/L). His resting electrocardiogram (ECG) was normal including the corrected QT interval (QTc) which was 0.40 sec. The results of the cardiac autonomic function tests demonstrated several abnormalities. The results are summarised in Table 1. Barium swallow radiographs revealed aperistalsis along the whole length of the oesophagus. There was no evidence of megaoesophagus or of filling defects to suggest achalasia or carcinoma of the oesophagus respectively (Figure). Indirect laryngoscopy and pharyngoscopy did not reveal any lesion.

\* To whom correspondence should be sent.



**Table: Results of autonomic nervous function tests**

Test	Results	*Normal Range	Remarks
Pulse (resting)	82/ min	60 – 100/min	Normal
30:15 ratio	1.00	≥1.04	Reduced
E:I ratio	1.00	≥1.20	Reduced
Valsalva ratio	1.46	≥1.21	Normal
Orthostatic SBP difference	30 mmHg	11–29 mmHg	Increased (abnormal)
Orthostatic DBP difference	10 mmHg	< 10 mmHg	Increased (abnormal)

E:I = Expiration : Inspiration  
 SBP = Systolic blood pressure  
 DBP = Diastolic blood pressure  
 \*Normal ranges from (7)

These clinical and radiological features overall were suggestive of oesophageal hypomotility from autonomic neuropathy. The patient was subsequently commenced on erythromycin

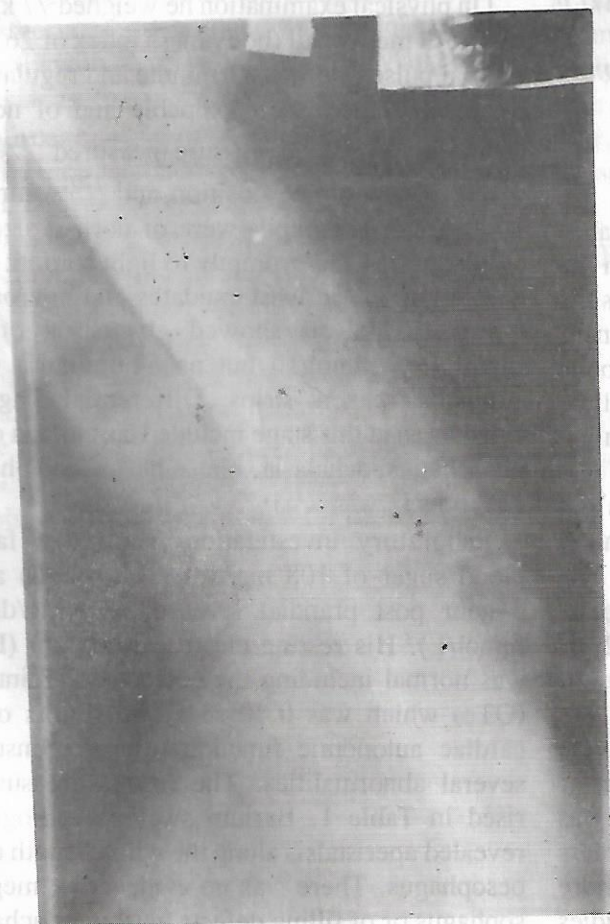
(250mg b.d. orally) for 3 weeks as well as metoclopramide (10mg t.d.s.) for one week. When seen a month later there was full relief of all symptoms of dysphagia. This relief was sustained even after the completion of the regimen. He remained asymptomatic for the dysphagia as at the last follow-up visit to the clinic almost a year after initial presentation.

## COMMENTS

DAN is a common but often unrecognised complication of diabetes (3,7). It may be unnoticed by the patient and physician alike because of its insidious onset, vagueness and often intermittent nature. Detection and monitoring of DAN are important as it has been associated with sudden death in affected individuals (8,9). Sudden death probably occurs as a result of fatal cardiac arrhythmias in those with cardiac denervation from DAN (9,10). The patient described in this report had evidence of cardiac denervation. Although his only symptom relevant to the cardiovascular system was postural dizziness, his cardiovascular autonomic nerve function tests were abnormal.

Cardiac autonomic function tests (tests for cardiac reflexes) objectively assess DAN as it affects the cardiovascular system (9,10,11). The QTc also provides a possible marker for the development of fatal cardiac arrhythmias (6,18). Other tests have also been used to assess autonomic function. These include pupillometry, sweat imprint tests, regional skin temperature differences, quantitative sudomotor axon reflex tests, assessment of bladder function and penile tumescence (7,12,13). This patient had a normal pupillary size and a prompt pupillary response to light but further tests on the pupil were not carried out.

In diabetics with dysphagia, the symptom is usually associated with chest pain (often described as heart-burn) and also neuropathic symptoms as demonstrated in our patient. Before a diagnosis of oesophageal motility disorder is made, conditions such as hiatus hernia, achalasia, oesophageal cancer



**Fig. Barium swallow showing aperistalsis of a long segment of the oesophagus.**



## DIABETIC AUTONOMIC DYSPHAGIA

and oesophageal candidiasis have to be excluded. The latter is commoner in diabetics than non-diabetics (2,3).

Treatment of oesophageal motility disorders due to DAN is based on the use of drugs which improve oesophageal motility such as motilin, a gastrointestinal tract hormone (14). Erythromycin, a macrolide antibiotic has also been found to be useful in the treatment of this condition. Its mode of action is probably by simulating the effects of motilin. This unusual property has been ascribed to the similarity in the chemical structure of the two substances (2,15). Metoclopramide is also used in the treatment of dysphagia due to DAN with good results (2,16). Domperidone is another drug that has been used with some success (2,17). The latter two drugs are dopamine antagonists. In the patient reported here, a combination of erythromycin and metoclopramide was used with a favourable outcome.

This case serves to highlight the importance of evaluating for DAN in diabetics with unusual symptoms and reinforces the opinion that cardiac denervation may not be as rare as many medical practitioners may think. Unpublished studies by our unit revealed cardiac denervation in as many as a third of non-insulin dependent diabetics studied. This case report also demonstrates the modern treatment of an important and distressing symptom of dysphagia, and other gastrointestinal symptoms due to autonomic neuropathy in diabetes mellitus.

## ACKNOWLEDGEMENT

We thank Prof O. Okeowo of the ENT unit and Dr. D. A. Olanrewaju of Radiology Dept. for their assistance.

## REFERENCE

- Greene DA, Sima AAF, Albers JW. Diabetic neuropathy. In: Rifkin H, Porte D Jr. (eds). *Ellenberg and Rifkin's Diabetes Mellitus*. Fourth Edition, Elsevier Publishing Company New York. 1990:711-755.
- May RJ, Goyal RK. Effects of diabetes on the digestive system. In: Kahn CR, Weir GC (eds). *Joslin's Diabetes Mellitus*. Lea and Febiger Publications, Philadelphia 1994: 921-954.
- Feldman M, Schiller LR. Disorders of the gastrointestinal motility associated with diabetes mellitus. *Ann Intern Med* 1983; **98**:378-384.
- Osuntokun BO, Akinkugbe FM, Francis TI, Reddy S, Osuntokun O, Taylor GOL. Diabetes Mellitus in Nigerians: A Study of 832 Patients. *West African Medical Journal* 1971; **20**:259-312.
- Horowitz M, Harding PE, Maddox AE. Gastric and oesophageal emptying in patients with Type 2 diabetes mellitus. *Diabetologia* 1989; **32**:151-159.
- Bazett HC. An analysis of the time relationship of the electrocardiogram. *Heart* 1920; **7**:353-370.
- Naghmi R. Diabetic autonomic neuropathy. *Practical Diabetes Digest*. 1991; **1**:69-73.
- Page MM, Watkins PJ. Cardiorespiratory arrests and diabetic autonomic neuropathy. *Lancet* 1978; **1**:14-16.
- Watkins PJ, Mackay JD. Cardiac denervation in diabetic neuropathy. *Ann Intern Med* 1980; **92**:304-307.
- Ewing DJ, Clarke BF. Diagnosis and management of diabetic autonomic neuropathy. *Br Med J* 1982; **285**:916-18.
- Tandon R, Bajpai HS, Agarwal JK. A comprehensive study autonomous system dysfunction in diabetes mellitus. *J Assoc. Physicians India* 1985;**33**:265-268.
- Clarke BF, Ewing DJ, Campbell IW. Diabetic autonomic neuropathy. *Diabetologia* 1979; **17**:195-212.
- Zorgniotti AW. Pharmacologic treatment of erectile dysfunction by intracavernous injection, In: Mogensen CE, Standl E (eds). *Pharmacology of Diabetes*. W de Gruyter Publications, Berlin. 1994:239-246.
- Schmid R, Schudziarra V, Allescher HD, Bofilias J, Buttermann G, Classen M. Effect of motilin on gastric emptying in patients with diabetic gastroparesis. *Diabetes Care* 1991; **14**:65-67.
- Zara GP, Qin XY, Pilot MA, Thompson HH, Maskell JP. Erythromycin and gastrointestinal motility. *Lancet* 1987; **2**:1036.
- Longstreth GF, Malagelada JR, Kelly KA. Metoclopramide stimulation of gastric motility and emptying in diabetic gastroparesis. *Ann Intern Med* 1977; **86**:195-196.
- Koch KL, Stern RM, Stewart WR, Vasey MW. Gastroparesis: Effect of long term domperidone treatment. *Am J Gastroenterol* 1988; **84**:1069-1075.
- Chambers JB, Sampson MJ, Springings DC, Jackson G. QT prolongation on the electrocardiogram in diabetic autonomic neuropathy. *Diabetic Med* 1990; **7**: 105-110.