

Case Report

A case report of a successfully managed advanced abdominal pregnancy with favorable fetomaternal outcomes

OSANYIN GE, OKUNADE KS, OYE-ADENIRAN BA

Department of Obstetrics and Gynaecology, College of Medicine, University of Lagos, Lagos University Teaching Hospital, Lagos, Nigeria

ABSTRACT

An abdominal pregnancy can be regarded as a form of an ectopic pregnancy where the embryo or fetus is growing and developing outside the uterus but within the abdominal cavity. While it is a very rare occurrence, abdominal pregnancies have a higher chance of maternal mortality, perinatal mortality, and morbidity compared to normal and ectopic pregnancies, but on occasion, a healthy viable infant can be delivered. We presented the case of a 40-year-old gravida 8 para 4⁺³ (4 alive) woman with intra-abdominal pregnancy who was first seen at 29 weeks' gestation with a history of abdominal pain and ultrasonographic findings of a live intra-abdominal fetus. She was managed conservatively till 34 weeks' gestation and was subsequently delivered by laparotomy with favorable maternal and fetal outcomes. The case is reported to highlight the successful outcome in spite of the difficulties in diagnosis and management in a low-resource setting.


Key words: Ectopic pregnancy; laparotomy; perinatal mortality.

Introduction

Ectopic pregnancy defined as a conceptus that implants outside of the uterine endometrium.^[1] It is responsible for 4%–10% of pregnancy-related deaths, especially in developing countries.^[2] Abdominal pregnancy is a relatively uncommon form of ectopic pregnancy accounting for about 1% of all cases. It is said to occur when the conceptus is found within the peritoneal cavity.^[3] An advanced abdominal pregnancy is so described when the pregnancy has gone beyond 20 weeks of gestation with signs of a fetus that is either living or having lived in the mother's peritoneal cavity.^[4] An advanced abdominal pregnancy with a live fetus is an even rarer event with few cases reported in literature.^[4,5] Abdominal pregnancy is associated with a significantly high maternal mortality rate of 0.5%–18% and an even higher perinatal mortality rate of 40%–95%.^[3,6]

Symptoms may include abdominal pain or vaginal bleeding during pregnancy.^[7] As this is nonspecific in areas where ultrasound is not available, the diagnosis was often only discovered during surgery to investigate the abnormal symptoms.^[7] They are typically diagnosed later in the developing world than the developed.^[8] In about half of cases from a center in the southeastern part of Nigeria, the diagnosis was initially missed.^[9] Diagnosis can be frequently missed in most poor-resource settings because of poor antenatal coverage, low socioeconomic status in most of the patients as well as lack of adequate medical resources.^[10] A high index of suspicion is crucial in clinching the diagnosis especially when the women present with the complications of abdominal

Address for correspondence: Dr. Gbemisola Eniola Osanyin, Department of Obstetrics and Gynaecology, College of Medicine, University of Lagos, PMB 12003, Lagos, Nigeria.
E-mail: ennybanks@yahoo.com

Access this article online	
Website: www.tjgonline.com	Quick Response Code 
DOI: 10.4103/TJOG.TJOG_9_17	

This is an open access article distributed under the terms of the Creative Commons Attribution-NonCommercial-ShareAlike 3.0 License, which allows others to remix, tweak, and build upon the work non-commercially, as long as the author is credited and the new creations are licensed under the identical terms.

For reprints contact: reprints@medknow.com

How to cite this article: Osanyin GE, Okunade KS, Oye-Adeniran BA. A case report of a successfully managed advanced abdominal pregnancy with favorable fetomaternal outcomes. *Trop J Obstet Gynaecol* 2017;34:240-2.

pain or hemoperitoneum.^[11] The pregnancy rarely progresses to term, and if they do, the fetuses more often than not are either dead or congenitally malformed. Advanced abdominal pregnancy is still rare, and guidelines for its management are yet unclear with few cases published to date in Africa.^[6,9] We present a case of an advanced abdominal pregnancy who was delivered at 34 weeks' gestation with a live baby without any malformation and good maternal outcome.

Case Report

A 40-year-old gravida 8 para 4⁺³ (4 alive) woman presented at the Accident and Emergency Department of the Lagos University Teaching Hospital at 29 weeks' gestation with a 3-day history of progressively worsening abdominal pain. The pain was described as sharp, initially localized to the right side of the abdomen, but later became generalized. The pain severity was described as 7 on a scale of 10 and was said to be aggravated by fetal movement which she still perceived adequately as at the time of presentation. She had no bleeding per vaginam, no drainage of liquor, and no gastrointestinal or urinary symptoms. There was no history of early pregnancy uterine instrumentation. On physical examination, she was anxious looking but not in obvious painful distress. Her vital signs were within normal limits, and her cardiovascular and respiratory system did not reveal any abnormality. There was mild generalized tenderness on abdominal examination with a fundal height of 26 cm and easily palpable fetal parts. Abdominal ultrasound scan done before presentation had shown a live fetus at 29 weeks' gestational age in transverse lie within the upper abdominal quadrants with the fetal head lodged between the spleen and left kidney and the lower limbs floating freely in the right lumbar region. The uterus was empty with endometrial lining of 2 mm, and the placenta appeared to be attached to the fundus. The patient was counseled on the findings, stabilized, and conservatively managed in the lying-in ward over the next 5 weeks. She had weekly ultrasound scan and biophysical profile done to monitor fetal growth and well-being. She was subsequently scheduled for an exploratory laparotomy at 34 weeks' gestation. Preoperative magnetic resonance imaging (MRI) showed a fetus lying freely in the peritoneal cavity. The placenta was located superior to the uterine fundus [Figure 1]. She had 6 units of blood cross-matched in anticipation of hemorrhage. The general surgeons were also invited for the surgery. Findings at surgery included a live male fetus lying transversely within the peritoneal cavity and surrounded by omentum. Birth weight was 2.5 kg and the Apgar score was 6 and 8 in 1 and 5 min, respectively. No anomaly was seen on the baby. The placenta was extensively attached to the omentum, large bowel, and uterine fundus. The umbilical cord was doubly ligated close to the placenta which was left *in situ*. The uterus, fallopian tubes,

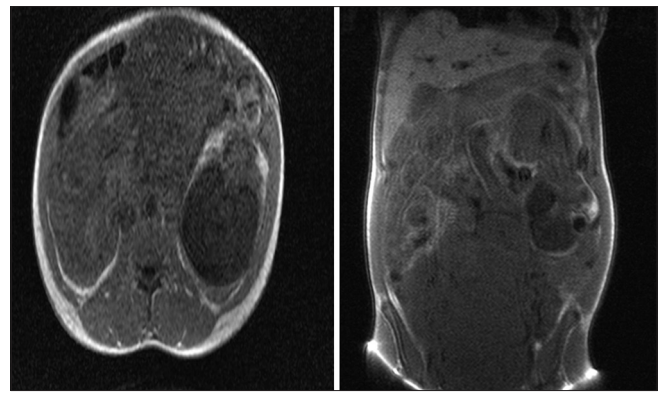


Figure 1: Preoperative magnetic resonance imaging showing the fetus lying freely in the peritoneal cavity. The placenta was located superior to the uterine fundus (second image)

and ovaries appeared normal. Intraoperative blood loss was 600 ml, and she did not require transfusion. Her postoperative period was uneventful, and she was discharged home with her baby 10 days after the surgery. She was seen 2 and 6 weeks postpartum with serial abdominopelvic ultrasound scans showing a progressive reduction in the placental size and no demonstrable flow on color Doppler. Qualitative beta-human chorionic gonadotropin (B-hCG) at the 6th-week follow-up visit was negative, and the ultrasound scan done at 6 months did not visualize the placenta.

Discussion

Due to the widely uncommon nature of abdominal pregnancy, a high index of suspicion is necessary for prompt diagnosis and appropriate management.^[3] The incidence of abdominal pregnancy varies between geographic regions but is found more in developing countries.^[11-13] The reported incidences were 1 in 10,000 deliveries in the USA,^[12] 1 in 654 in Ibadan, Nigeria^[13] and 1 in 1320 in Kumasi, Ghana.^[11] The incidence is also said to appear higher in multiparous women and women of low socioeconomic status.^[13]

Abdominal pregnancy is classified as primary or secondary. Primary abdominal pregnancy is said to occur when implantation of the fertilized ovum is directly within the peritoneal cavity.^[3] In such cases according to Studdiford criteria, the ovaries and tubes appear normal, there is no uteroperitoneal fistula, and the pregnancy is exclusively on the peritoneal surface.^[3,14] Secondary abdominal pregnancy is the more common of the two where there is a secondary implantation of a primary tubal pregnancy in the peritoneal cavity.^[11] Primary abdominal pregnancy is rarely seen.^[4]

Clinical features of abdominal pregnancy are most commonly abdominal pain;^[12] however, features range from being asymptomatic to acute abdomen, fetal malpresentation, easily

palpable fetal parts, or fetal demise.^[3,12,14] Ultrasonography is a very important tool in the diagnosis of an extrauterine pregnancy while other radiologic studies such as MRI and computed tomography scan are also very helpful but unfortunately not readily available or affordable in most third world countries and as such a high index of suspicion is needed for prompt diagnosis and timely intervention to prevent life-threatening complications.^[11]

Potential treatments of abdominal pregnancy consist of surgery with termination of the pregnancy (removal of the fetus) through laparoscopy or laparotomy, use of methotrexate, embolization, and combinations of these. Sapuri and Klufio indicated that conservative treatment is also possible if the following criteria are met: there are no major congenital malformations; the fetus is alive; there is continuous hospitalization in a well-equipped and well-staffed maternity unit which has immediate blood transfusion facilities; there is careful monitoring of maternal and fetal well-being; and placental implantation is in the lower abdomen away from the liver and spleen.^[15] The choice is largely dictated by the clinical situation, but generally, treatment is indicated when the diagnosis is made. Our patient met all the criteria for conservative management and was subsequently delivered by laparotomy at 34 weeks' gestation.

Major hemorrhage from placental implantation site is often the most common cause of maternal mortality and as such decision to remove or leave placenta *in situ* depends on the extent of placentation and skills of the surgeon.^[4,11] It is usually recommended to leave the placenta *in situ* and monitor the hCG levels.^[11] MRI has been used with success to plan for surgery^[16,17] just like in our patient who had a preoperative MRI to ascertain the location of the fetus and the placenta and thus provide the necessary guide to the surgeons by ensuring the availability of certain additional interventions to forestall complications.

Conclusion

An abdominal pregnancy with a healthy newborn is a rare occurrence. For abdominal pregnancies diagnosed before 20 weeks, termination is usually advised; however, an advanced abdominal pregnancy is managed expectantly with the aim of delivery at 34 weeks of gestation when fetal lung maturity is certain. The removal of placenta is for well-selected cases and is usually dependent on findings during surgery as well as the skills of surgeon otherwise it is advised to leave placenta *in situ*. However, standardization of the treatment principles for advanced abdominal pregnancy, perioperative treatment options, and postoperative management measures would improve newborn survival, reduce complications, and mortality.

Declaration of patient consent

The authors certify that they have obtained all appropriate patient consent forms. In the form the patient(s) has/have given his/her/their consent for his/her/their images and other clinical information to be reported in the journal. The patients understand that their names and initials will not be published and due efforts will be made to conceal their identity, but anonymity cannot be guaranteed.

Financial support and sponsorship

Nil.

Conflicts of interest

There are no conflicts of interest.

References

1. Marion LL, Meeks GR. Ectopic pregnancy: History, incidence, epidemiology, and risk factors. *Clin Obstet Gynecol* 2012;55:376-86.
2. Varma R, Gupta J. Tubal ectopic pregnancy. *BMJ Clin Evid* 2012;2012. pii: 1406.
3. Mengistu Z, Getachew A, Adefris M. Term abdominal pregnancy: A case report. *J Med Case Rep* 2015;9:168.
4. Nassali MN, Benti TM, Bandani-Ntsabele M, Musinguzi E. A case report of an asymptomatic late term abdominal pregnancy with a live birth at 41 weeks of gestation. *BMC Res Notes* 2016;9:31.
5. Masukume G. Live births resulting from advanced abdominal extrauterine pregnancy, a review of cases reported from 2008 to 2013. *WebmedCentral Obstet Gynaecol* 2014;5:WMC004510.
6. Adesiyun AG, Audu AI. Term extrauterine pregnancy in a Nigerian mother: A complication of uterine dehiscence. *Arch Gynecol Obstet* 2009;279:75-7.
7. Nkusu Nunyalulendho D, Einterz EM. Advanced abdominal pregnancy: Case report and review of 163 cases reported since 1946. *Rural Remote Health* 2008;8:1087.
8. Onoko O, Petru E, Masenga G, Ulrich D, Obure J, Zeck W, *et al.* Management of the placenta in advanced abdominal pregnancies at an east African tertiary referral center. *J Womens Health (Larchmt)* 2010;19:1369-75.
9. Sunday-Adeoye I, Twomey D, Egwuatu EV, Okonta PI. A 30-year review of advanced abdominal pregnancy at the mater misericordiae hospital, Afikpo, Southeastern Nigeria (1976-2006). *Arch Gynecol Obstet* 2011;283:19-24.
10. Dabiri T, Marroquin GA, Bendek B, Agamasu E, Mikhail M. Advanced extrauterine pregnancy at 33 weeks with a healthy newborn. *Biomed Res Int* 2014;2014:102479.
11. Baffoe P, Fofie C, Gandau BN. Term abdominal pregnancy with healthy newborn: A case report. *Ghana Med J* 2011;45:81-3.
12. Zhang J, Sheng Q. Full-term abdominal pregnancy: A case report and review of literature. *Gynecol Obstetrics Invest* 2008;65:139-41.
13. Ayinde OA, Aimakhu CO, Adeyanju OA, Omigbodun AO. Abdominal pregnancy at the university college hospital, Ibadan: A ten-year review. *Afr J Reprod Health* 2005;9:123-7.
14. Poole A, Haas D, Magann EF. Early abdominal ectopic pregnancies: A systematic review of the literature. *Gynecol Obstet Invest* 2012;74:249-60.
15. Sapuri M, Klufio C. A case of advanced viable extrauterine pregnancy. *P N G Med J* 1997;40:44-7.
16. Dahiya K, Sharma D. Advanced abdominal pregnancy: A diagnostic and management dilemma. *J Gynecol Surg* 2007;23:69-72.
17. Lockhat F, Corr P, Ramphal S, Moodley J. The value of magnetic resonance imaging in the diagnosis and management of extra-uterine abdominal pregnancy. *Clin Radiol* 2006;61:264-9.