

ORIGINAL RESEARCH REPORT

Intestinal malrotation in the older child: A call for vigilance

Oluwafunmilayo Funke Adeniyi, Elizabeth O. Ajayi, Olumide A. Elebute¹, Mary A. Lawal

Department of Paediatrics, College of Medicine, University of Lagos, Lagos University Teaching Hospital, ¹Department of Surgery, Paediatric Surgery Unit, Lagos University Teaching Hospital, Lagos, Nigeria

ABSTRACT

Context: Most cases of gut malrotation are diagnosed in the 1st year of life, but in minority of cases, the patient becomes symptomatic only in adolescence or adulthood. **Aims:** The aim of this study was to remind physicians to include intestinal malrotation in the differential diagnosis of children who present with recurrent abdominal pain, especially when it is associated with vomiting and other gastrointestinal symptoms. **Settings and Design:** This was an audit of the older children with gut Malrotation who presented to the Lagos University Teaching Hospital (LUTH). **Subjects and Methods:** The clinical records of children above the age of 1 year who presented with recurrent abdominal pain and/or vomiting between January 2013 and October 2015 at the LUTH were reviewed. Clinical features, radiological findings, and operation findings were documented. **Statistical Analysis:** Data were analyzed using the SPSS version 21 (SPSS Statistics for Windows, version 21.0, IBM Corp., USA). Data were presented in frequency and percentages. **Results:** Five patients with gut malrotation were seen during the study period. The median age was 7.0 years (range: 15 months–10 years). The most common complaint was intermittent colicky abdominal pain and recurrent vomiting in 5 (100%). Preoperative diagnosis was possible in 3 patients, with the use of abdominal computerized tomography scan. Operative findings included obstructing bands of Ladd, volvulus with situs inversus. Symptoms were relieved satisfactorily with surgical intervention. **Conclusions:** There is a need for a high index of suspicion for intestinal malrotation in children who present with a prolonged history of recurrent abdominal pain and vomiting irrespective of the age. Imaging enables accurate diagnosis and most effective treatment is surgical.

Key words: Intestinal malrotation, older child, recurrent abdominal pain, vomiting

Address for correspondence:

Dr. Oluwafunmilayo Funke Adeniyi,
Department of Paediatrics,
College of Medicine, University of
Lagos, Lagos University Teaching
Hospital, Idi Araba, Lagos, Nigeria.
E-mail: layo_funke@yahoo.co.uk

INTRODUCTION

Malrotation of the gut refers to abnormal positioning of the intestine within the peritoneal cavity and this may involve the small intestine or the large intestine.^[1] Midgut malrotation usually results when the counterclockwise rotation of the gut does not take place and the duodenojejunal (DJ) junction is displaced to the right of the midline.^[1,2] This is usually accompanied with nonrotation and incomplete rotation of the superior mesenteric artery. The incidence of the condition is said to be about 1 in 6000 births^[3] and 85% of cases present in the first 2 weeks of life. However, in minority of cases, the patient

becomes symptomatic only in adolescence or adulthood. Some individuals actually remain asymptomatic and are never diagnosed throughout their lifetime.^[2] The classical presentation of malrotation in the newborn period is bilious vomiting with or without abdominal distension.^[2] However, the clinical features in the older children or adults may be difficult to elucidate, but available reports have documented the following features: recurrent abdominal pain, nausea and vomiting, failure to thrive, abdominal distension, and features of malabsorption syndrome.^[4,5]

This is an open access article distributed under the terms of the Creative Commons Attribution-NonCommercial-ShareAlike 3.0 License, which allows others to remix, tweak, and build upon the work non-commercially, as long as the author is credited and the new creations are licensed under the identical terms.

For reprints contact: reprints@medknow.com

How to cite this article: Adeniyi OF, Ajayi EO, Elebute OA, Lawal MA. Intestinal malrotation in the older child: A call for vigilance. J Clin Sci 2017;14:200-3.

Access this article online

Quick Response Code:



Website:

www.jcsjournal.org

DOI:

10.4103/jcls.jcls_53_17

SUBJECTS AND METHODS

RESULTS

The median age of the children with malrotation was 7.0 years (range: 15 months–10 years). Eighty percent of the subjects with the condition were aged 5 years and above. The most common presenting symptoms were intermittent colicky abdominal pain in 5 (100%) and recurrent vomiting in 5 (100%) of the subjects. Vomiting was bilious in 4 (80%) of the cases. These symptoms dated back to infancy in 80% of the subjects. Other clinical features included failure to thrive, weight loss, and fever in 2 (40.0%) of the patients, respectively. One of the patients, a 15-month-old male child had genotype SS; another subject, a 10-year-old male had genotype AC.

Preoperative diagnosis was possible in 3 (50%) patients, with the use of Abd CT scan and this revealed situs inversus [Figure 1] (right-sided stomach and left-sided liver and gall bladder) and midgut volvulus in the one of the patients.

DISCUSSION

1000 11.25 100
 0.00 / 00 11.0615751000 /
 P 100
 F 100
 FOREMOST RADIOLOGY CONSULTANTS
 JACOBSON TANTO TONG
 R S. PAUL / 01 / 05 / 701
 18 May 2015
 512
 HF 1.6
 1000 11.25 100
 0.00 / 00 11.0615751000 /
 P 100
 F 100
 FOREMOST RADIOLOGY CONSULTANTS
 JACOBSON TANTO TONG
 R S. PAUL / 01 / 05 / 701
 18 May 2015
 512
 HF 1.6

Figure 1: Abdominal computerized tomography scan showing intestinal malrotation (original)

Table 1: Clinical, intraoperative findings and outcome in the subjects

Cases	Age (years)	Gender	Clinical presentation	Intraoperative findings	Outcome
1	5	Male	Abdominal pain, vomiting	Midgut malrotation	Survived
2	9	Female	Abdominal pain, vomiting, weight loss, failure to thrive	Midgut malrotation	Survived
3	10	Male	Abdominal pain, vomiting, bilious	Midgut malrotation (180°) with Ladd's band that was adherent to the cecum	Survived
4	10	Female	Abdominal pain, vomiting	Incomplete rotation with obstructing Ladd's bands. Situs inversus: Right-sided stomach was seen, while the liver and the gall bladder were on the left side of the abdomen	Survived
5	15 months	Male	Abdominal pain, bilious vomiting, distension, weight loss	Incomplete midgut malrotation, subhepatic cecum, appendix bound by Ladd's band to posterior abdominal wall. DJ was to the right and SMV to the left	Survived

SMV=Superior mesenteric vein, SMA=Superior mesenteric artery, DJ=Duodenojejunal junction

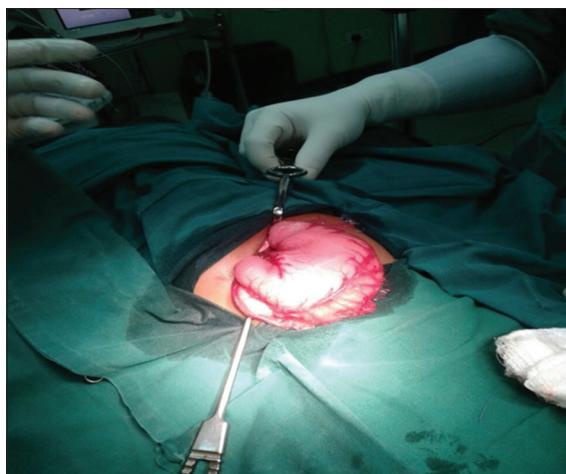

Figure 2: Intraoperative finding of gut malrotation showing dilated gastrium (original)

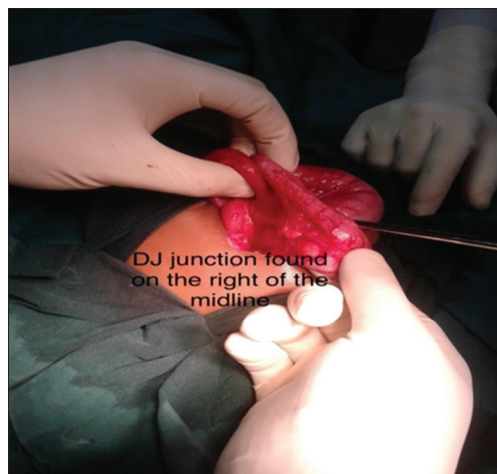


Figure 3: Showing duodenojejunal junction to the right of the midline (original)

and the common clinical features among the patients were abdominal pain and vomiting. In a case series of gut malrotation by Nasir *et al.*, in 2011,^[6] nine cases of gut malrotation were documented and two of the cases were aged 3 and 13 years, respectively. These children also presented with abdominal pain and bilious vomiting. Nwankwo and Gboobo^[7] in Port Harcourt observed in an audit of patients with gut malrotation over a 5-year period that 8 (36.3%) of the 22 patients diagnosed were more than 2 years of age with all presenting with essentially the same symptomatology.

However, in older children, other clinical features such as failure to thrive and malabsorption syndrome have also been documented. Two of our patients had failure to thrive and weight loss in addition to abdominal pain and vomiting. Nakajima *et al.*^[1] in Japan reported a case of malrotation of gut in a 14-year-old boy while Uwaezuoke and Udoe^[8] described a 27-year-old man who was initially thought to have appendicitis, but further reevaluation revealed a gut malrotation.

It must be noted that the diagnosis of malrotation in the teenagers may be difficult and a number of patients may be asymptomatic and some may even live their entire lives without any complaint.^[1] The absence of specific signs and few signs, especially in the teenage years, usually results in difficulty in making a diagnosis, but most reports have noted that abdominal pain remains a constant feature. However, the site of the abdominal pain in the older children/adults is not specific and so is the nature of the pain which may vary from a persistent aching to a colicky abdominal pain. Pain may be worse with meals and frequency or interval is quite variable.^[9] The subjects in this study had mainly intermittent and colicky abdominal pain.

In terms of sex predilection, most authors have observed a male preponderance for the condition.^[6,7] However, in this

study, there was an equal sex distribution which is similar to the finding of Ameh and Chirdan in Zaria.^[10]

Malrotation of the gut can occur in isolation or it may be associated with other congenital anomalies even in the older child. Such anomalies include the following: absence of kidney and ureter, biliary atresia, congenital diaphragmatic hernia, duodenal or small-bowel stenosis or atresia, duodenal web, gastroschisis, Hirschsprung disease, imperforate anus, intestinal pseudoobstruction, intussusception, meckel diverticulum, omphalocele, pyloric stenosis, and situs inversus.^[2,11] One of the subjects in this study, a 9-year-old female had situs inversus with a right-sided stomach and left-sided liver and gall bladder. Nwankwo and Gboobo^[7] on the other hand observed duodenal atresia (44.4%), jejunoileal atresia (22.2%), renal agenesis (5.5%), and intussusception (11%) in their series.

In making a diagnosis of malrotation in any age group, abdominal X-rays may not be very useful; it may be normal or may show distension of the stomach and proximal duodenum by air, with paucity of gas in the distal bowel.^[1] Only one of the subjects in our series had this finding. The upper GI series is believed to be a more reliable diagnostic tool for intestinal malrotation and the sensitivity varies from 93% to 100%.^[2,11-13] However, preoperative diagnosis is best made with an Abd CT scan, but if not available, then an upper GI series with contrast could be diagnostic.^[2] Abd CT scan was diagnostic in 3 (60%) of our patients, and this imaging also enabled the diagnosis of situs inversus to be made in one of the subjects.

In terms of complications, midgut volvulus is the most fatal witnessed in this condition and this has also been reported in older children and even in the adults.^[1,11-13] This was also observed in this study.

Treatment of gut malrotation requires exploratory laparotomy, even if the patient is asymptomatic as there is a constant risk

Adeniyi, *et al.*: Intestinal malrotation in the older child

of volvulus and vascular compromise, especially with delay in treatment.^[1] In our series, the patient with the volvulus did the Abd CT scan 6 months after the request was made due to financial constraints and thus had the complication by the time the exploratory laparotomy was done.

Prognosis of the condition remains excellent with appropriate and early intervention.^[1] However, prognosis may also be influenced by other associated anomalies.

CONCLUSIONS

Malrotation of the intestine though commonly seen in infancy is a condition that should be suspected in older children and adults when the patient present with prolonged and recurrent abdominal pain and vomiting. There is a need to have a high index of suspicion for the condition and the use of the Abd CT enhances diagnosis and detection of other associated anomalies.

Financial support and sponsorship

Nil.

Conflicts of interest

There are no conflicts of interest.

REFERENCES

1. Nakajima Y, Sakata H, Yamaguchi T, Yoshie N, Yamada T, Osako T, *et al.* Successful treatment of a 14-year-old patient with intestinal malrotation with laparoscopic Ladd procedure: Case report and literature review. *World J Emerg Surg* 2013;8:19.
2. Applegate KE, Anderson JM, Klatte EC. Intestinal malrotation in children: A problem-solving approach to the upper gastrointestinal series. *Radiographics* 2006;26:1485-500.
3. Uba AF, Chirdan LB, Edino ST. Intestinal malrotation: Presentation in the older child. *Niger J Med* 2005;14:23-6.
4. Imamoglu M, Cay A, Sarihan H, Sen Y. Rare clinical presentation mode of intestinal malrotation after neonatal period: Malabsorption-like symptoms due to chronic midgut volvulus. *Pediatr Int* 2004;46:167-70.
5. Pierro A, Ong EG. Malrotation. In: Puri P, Hollwart ME, editors. *Pediatric Surgery*. New York: Springer-Verge Berlin Heidelberg; 2004. p. 197-201.
6. Nasir AA, Abdur-Rahman LO, Adeniran JO. Outcomes of surgical treatment of malrotation in children. *Afr J Paediatr Surg* 2011;8:8-11.
7. Nwankwo NC, Gboobo I. Malrotation of the intestine in children in Port Harcourt, South-South Nigeria: Review of 26 cases. *J Med Med Sci* 2011;2:1291-6.
8. Uwaezuoke SC, Udoye EP. Gangrenous adult midgut volvulus from midgut malrotation: A case report. *JDMS* 2014;1:93-5.
9. Nehra D, Goldstein AM. Intestinal malrotation: Varied clinical presentation from infancy through adulthood. *Surgery* 2011;149:386-93.
10. Ameh EA, Chirdan LB. Intestinal malrotation: Experience in Zaria, Nigeria. *West Afr J Med* 2001;20:227-30.
11. Torres AM, Ziegler MM. Malrotation of the intestine. *World J Surg* 1993;17:326-31.
12. Lin JN, Lou CC, Wang KL. Intestinal malrotation and midgut volvulus: A 15-year review. *J Formos Med Assoc* 1995;94:178-81.
13. Seashore JH, Touloukian RJ. Midgut volvulus. An ever-present threat. *Arch Pediatr Adolesc Med* 1994;148:43-6.